

Medical Science

To Cite:

Krych G, Kazimierski B, Rusak A, Oklińska J, Skóra M, Jadczyk K, Gniado W, Mądry D. Urolithiasis in pregnancy – diagnostic management and proper treatment. A literature review. *Medical Science* 2026; 30: e81ms3869
doi:

Authors' Affiliation:

¹Provincial Complex Hospital named after Jędrzej Śniadecki in Białystok, ul. M. Curie-Skłodowskiej 26, 15-950 Białystok, Poland

²The Nicolaus Copernicus Municipal Polyclinical Hospital in Olsztyn, ul. Niepodległości 44, 10-045 Olsztyn, Poland

³University Clinical Hospital in Białystok, ul. M. Curie-Skłodowskiej 26, 15-276 Białystok, Poland

*Corresponding author:

Gabriela Krych,

Provincial Complex Hospital named after Jędrzej Śniadecki in Białystok, ul. M. Curie-Skłodowskiej 26, 15-950 Białystok, Poland,

ORCID: 0009-0005-6873-5358,

E-mail: krych55@gmail.com,

Phone: +48-662-065-644.

ORCID List:

Gabriela Krych	0009-0005-6873-5358
Bartłomiej Kazimierski	0009-0007-4480-5440
Aleksandra Rusak	0009-0006-7366-3368
Joanna Oklińska	0009-0001-5779-0539
Michał Skóra	0009-0001-5137-9490
Klaudia Jadczyk	0000-0002-2214-8319
Weronika Gniado	0009-0002-5676-3456
Dawid Mądry	0009-0003-5948-4548

Peer-Review History

Received: 15 May 2025

Reviewed & Revised: 09/June/2025 to 16/April/2026

Accepted: 25 April 2026

Published: 03 May 2026

Peer-review Method

External peer-review was done through double-blind method.

Medical Science

pISSN 2321-7359; eISSN 2321-7367



© The Author(s) 2026. Open Access. This article is licensed under a [Creative Commons Attribution License 4.0 \(CC BY 4.0\)](https://creativecommons.org/licenses/by/4.0/), which permits use, sharing, adaptation, distribution and reproduction in any medium or format, as long as you give appropriate credit to the original author(s) and the source, provide a link to the Creative Commons license, and indicate if changes were made. To view a copy of this license, visit <http://creativecommons.org/licenses/by/4.0/>.

Urolithiasis in pregnancy – diagnostic management and proper treatment. A literature review

Gabriela Krych^{1*}, Bartłomiej Kazimierski¹, Aleksandra Rusak², Joanna Oklińska¹, Michał Skóra¹, Klaudia Jadczyk³, Weronika Gniado¹, Dawid Mądry¹

ABSTRACT

Out of every 200 to 2000 pregnancies, 1 will have urolithiasis or urinary tract stones, making urolithiasis one of the leading causes of non-pregnancy-related hospitalizations among pregnant women. The majority of cases of urolithiasis occur during the second and third trimesters, especially in women who have delivered at least once previously. The complications associated with urolithiasis include preterm labor, preeclampsia, urosepsis, and renal failure, and can endanger both mother and fetus. Diagnosing urolithiasis in pregnant women can be quite challenging. The limitations of imaging studies additionally complicate the situation. As a result, many healthcare professionals mistakenly misdiagnose this condition in pregnant patients. Although ultrasonography is the preferred imaging modality for diagnosing urolithiasis, it has limitations regarding both sensitivity and inter-operator variability. Transvaginal ultrasound improves the identification of distal ureteral stones. Magnetic Resonance Imaging (MRI) is another option for diagnosing urolithiasis and is very sensitive, but it is not a great option because of limited access/availability and time constraints. Low-dose computed tomography (CT) is a viable option for difficult diagnoses but poses a risk for radiation exposure, so it should be reserved for difficult cases only. Generally, management of kidney stones begins conservatively with pain management and hydration; however, some patients may require surgical interventions such as Double-J stent placement, nephrostomy, or ureteroscopy; therefore, this study must serve as a synthesis of current clinical guidelines for providing evidence-based management for renal calculi (kidney stones) in pregnant women.

Keywords: urolithiasis, renal colic, pregnancy, ureteral stent, nephrostomy

1. INTRODUCTION

Urolithiasis complicates 1 out of every 200 to 1 out of every 2000 pregnancies and is the leading cause of non-pregnancy-related hospitalizations in pregnant women (Juliebo-Jones et al., 2022); the rates of urolithiasis amongst this category of patients are similar to those observed in the general population (Salehi-Pourmehr et al., 2023). On the whole, diagnosing and treating urolithiasis in pregnant women is also significantly more complex than in non-pregnant women because of special

requirements and limitations associated with this category of patients. According to an 11-year study (Chan et al., 2023), women with a history of pregnancy are at a greater risk of developing urolithiasis than those who have never been pregnant. The majority of pregnancies with urolithiasis occur between 20 and 39 weeks of gestation (66% and 34%, respectively). Urolithiasis during pregnancy represents a threat to both the mother and unborn child, while also producing significant adverse pregnancy outcomes such as premature labor, preeclampsia, and gestational hypertension. Without diagnosis and treatment as soon as possible, but with proper treatment when indicated, such as urosepsis or renal failure, without intervention for preterm labor, placental abruption, or death of mother and child (Radu et al., 2022). A misdiagnosis rate of 1/3 among kidney stone patients may delay both diagnosis and treatment (Juliebo-Jones et al., 2022). Patients with kidney stones at the hospital present with the following: lumbar or abdominal pain (85%); microscopic hematuria (95%); macroscopic hematuria (20%); pyuria (42%); and lower urinary tract symptoms (LUTS).

Typical symptoms of kidney stones across all major populations include lumbar pain and microscopic hematuria, which can be present in normal pregnancy and are less likely to imply kidney stones in a patient. Frequently misdiagnosed conditions (in order from most common) include appendicitis, placental abruption, or diverticulitis (Soffner Cardoso and Lopes Neto, 2022). The inability to perform CT imaging on pregnant patients is another factor that causes the delay in reaching a proper kidney stone diagnosis. While CT is considered the gold standard imaging modality for diagnosing kidney stones in the general population, it is not appropriate to use it due to the teratogenic effects of radiation exposure to the fetus. In this study, the intent is to recommend optimal diagnosis and care for pregnant patients with kidney stones based on the most up-to-date guidelines and current literature to improve care for pregnant women with kidney stones.

Aim of the study

The goal of this study is to provide a conclusion, based on the most recent guidelines and available research, on the best possible diagnostic and treatment options for pregnant women with urolithiasis. The focus of this study is on improving the quality of care for pregnant women diagnosed with urolithiasis by addressing the unique characteristics of this population in diagnosis and treatment. This study will aim to improve diagnostic accuracy, provide safe and effective treatment options, and ultimately enhance the overall health of both the mother and the fetus.

2. REVIEW METHODS

The authors reviewed all online literature for this article. Common sources of peer-reviewed literature included PubMed and Google Scholar, as well as common websites related to medicine (e.g., hospitals, universities), the European Association of Urology (EAU), and the American College of Obstetricians and Gynecologists (ACOG, 2017) Guidelines.

We searched for the most recent guidelines on pregnancy and urolithiasis, selecting only those articles we could find; we excluded non-English-language publications, articles without a full-text version available online, and articles published more than 5 years ago. The reason for limiting to the most recent available literature was to create a comprehensive review to inform our education on the topic; we wanted to take an academic perspective on urolithiasis in pregnancy. By using the latest scientific data and guidelines, our work reflects the state of medical development. The screening process of the articles follows the PRISMA guidelines (Figure 1).

3. RESULTS & DISCUSSION

The research indicates that ultrasonography is the best initial test for evaluating urolithiasis in pregnant patients; it is safe and readily available, though it has some drawbacks as an imaging modality. Doctors identified distal ureteric stones more reliably using transvaginal ultrasounds than in other formats. The second-best option for diagnosing urolithiasis is MRI, as it is highly sensitive and safe. Low-Dose CT can provide an additional option to other imaging modalities when the healthcare provider has counseled the patient on the potential risks before proceeding. A large majority of uncomplicated urolithiasis respond favorably to conservative therapy, with an average of over 70% having spontaneous stone passage from the ureter. Approximately one-third of patients will ultimately have to undergo a surgical procedure to treat their urolithiasis. Other treatment modalities, such as double-J stents and percutaneous nephrostomy tubes, are commonly used but are prone to encrustation and often require frequent replacement. Ureteroscopy has become a reliable and effective definitive treatment modality for urolithiasis.

To sum up, establishing a multidisciplinary approach to assessment and management of urolithiasis in pregnant patients is essential when used in conjunction with current guidelines. The best evidence-based imaging modality for pregnant patients is ultrasound or MRI, as a primary diagnostic tool. When considering treatment options, the provider should weigh the pros and cons of non-invasive

treatment versus surgical intervention to ensure patients receive the maximum benefit from the chosen treatment, both for the patient and for the developing fetus.

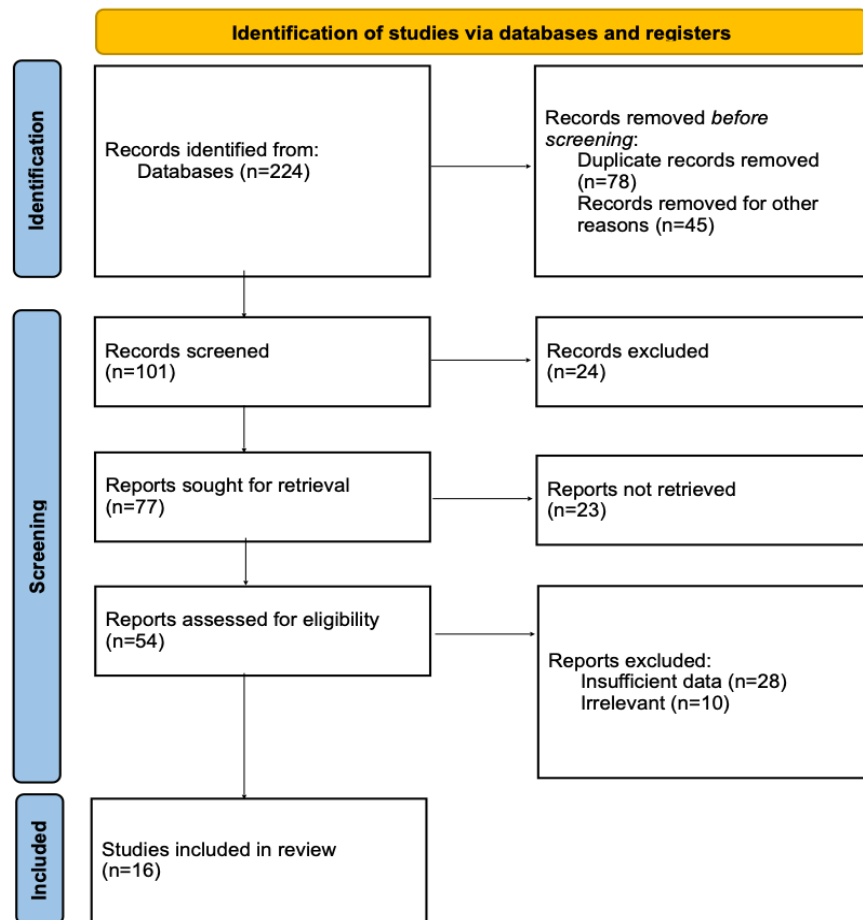


Figure 1. The screening process of the articles as PRISMA guidelines

Diagnostic evaluation

First, a healthcare professional must complete a full examination of the patient along with diagnostic lab testing. Healthcare providers should perform a full blood count; measure creatinine levels; assess blood urea nitrogen (BUN); evaluate inflammation markers (such as CRP); and conduct general urine testing and urine cultures (Cretu et al., 2022). These tests evaluate inflammation and kidney function to determine whether to initiate antibiotics. In addition, when there is a suspicion in pregnant women that they may have renal colic, they need to see a gynecologist to evaluate the status of the fetus and rule out obstetrical reasons for the pain that are not related to renal calculi. In one study, N'gamba et al., (2015) found that healthcare workers referred only 82 pregnant patients for evaluation of kidney stones. Of those, 29.3% of patients were diagnosed with kidney stones. Imaging studies can then aid the diagnostic process.

Ultrasonography – the study of choice

Ultrasonography remains the gold standard for diagnosing. According to the EAU guidelines, it should be the imaging of choice (EAU Guidelines, 2024).

This examination does not emit ionizing radiation, so it does not pose a risk of carcinogenic or teratogenic effects on the fetus; it is also inexpensive and widely available. Unfortunately, operator variability limits the effective elucidation of the cause of detected hydro-nephrosis (i.e., whether it is physiological or due to urinary tract obstruction by a stone). One alternative method for locating stones, particularly those distally in the ureter, is trans-vaginal ultrasound (TVUS) rather than abdominal ultrasound (USG). The study by Bold et al. confirmed that among stones located in the distal ureter, TVUS detects 94% of them, while standard USG detects only

29% (Bold et al., 2021). Another important aspect of ultra-sound is the presence or absence of so-called "ureteric jets". Their absence on one side has 100% sensitivity and 91% specificity for ipsilateral ureteral obstruction caused by a stone in its distal segment.

However, since up to 15% of pregnant women may not exhibit ureteric jets, healthcare providers must evaluate ultrasound results in the context of other examinations before (Juliebø-Jones et al., 2020). Another ultrasonographic feature aimed at improving diagnostic accuracy in detecting obstructive stones during pregnancy is the intrarenal resistive index (RI; peak systolic velocity–end–diastolic velocity/peak systolic velocity). Among pregnant women with renal colic and confirmed stones, a mean RI of 0.7 had a sensitivity of 45% and specificity of 91% for confirming a stone-causing obstruction. A difference in this index between kidneys of 0.06 showed 95% sensitivity and 100% specificity for stones in the same population. This index significantly aids in distinguishing physiological hydronephrosis from that caused by kidney stones (Dai et al., 2021).

MR – second line imaging study

If ultrasound is insufficient, the EAU recommends magnetic resonance imaging (MRI) as the second choice (EAU Guidelines, 2024). With non-ionizing radiation, it is safe for the fetus, and it is an alternative to USG. Studies have shown that infants who underwent multiple MRI examinations after the 20th week of gestation did not exhibit any abnormalities at 9 months of age (Clements et al., 2000). Magnetic resonance urography (MRU) is a type of MRI that uses gadolinium-based contrast to create a picture of the kidneys and urinary tract, although it can not directly visualize stones (however, they manifest as signal voids), and provides high sensitivity (82%) and specificity (98%) (Chan et al., 2023). During MRU, clinicians use gadolinium-based contrast agents to improve imaging, but it is not recommended due to potential toxicity (EAU Guidelines, 2024). MRI can detect other causes of abdominal pain in pregnant women, such as appendicitis. Researchers described several faster protocols than standard MRI for detecting small stones, such as thin-slice, fast spin-echo (FSE) and half-Fourier acquisition single-shot turbo spin-echo (HASTE) (Juliebø-Jones et al., 2022).

Low-dose CT scan – to be considered as a last option

In general, computed tomography (CT) is considered the gold standard for detecting kidney stones, with sensitivities and specificities exceeding 98% (Salehi-Pourmehr et al., 2023). However, the high doses of ionizing radiation generated during the examination have a proven harmful effect on the fetus, making it contraindicated in pregnant women. They have teratogenic effects and can lead to, among other things, miscarriage, growth retardation, severe intellectual impairment, or microcephaly. The risk of childhood cancer from radiation exposure is not established (Dai et al., 2021); however, if an adequate fetal dose absorbed from radiological exposure exceeds 0.5 mGy, the procedure will need to be justified as performed for a valid reason (EAU Guidelines, 2024). There is potential to obtain high-quality diagnostic images with very low radiation doses (<3.5 mSv) or extremely low doses (<1.9 mSv) when performing CT scans. Pregnant women would theoretically benefit from low-dose CT scans. In non-pregnant females, low-dose CT scans showed high sensitivity (>96%), specificity (>96%), and positive predictive value (>99%) (Soffner et al., 2022). However, it is much more complicated when evaluating females with a BMI higher than 30 kg/m² and stones measuring 3 mm or less (Chan et al., 2023). It is important to note that, when comparing the use of low-dose CT versus magnetic resonance imaging and ultrasound for the diagnosis of urolithiasis during pregnancy, low-dose CT has a higher positive predictive value (95.8% vs. 80% vs. 77%, respectively). Nevertheless, due to limited availability and a lack of established protocols, low-dose and ultra-low-dose CT studies are underutilized. The intent of utilizing low-dose CT protocols is as a last option (EAU Guidelines, 2024).

The decision to choose it should be preceded by a discussion with the patient and informing them about the risks associated with even low radiation doses. A team of obstetricians and radiologists should collaboratively make it.

Treatment

The treatment team can divide the treatment of a pregnant woman with kidney stones into two main pathways. The first one is conservative treatment, and the second one is surgical intervention. Choosing the right course of action is often difficult, not only because of the pregnancy itself but also due to the need for numerous consultations with specialists from other fields. The consultations often take a long time, delaying treatment.

First path – conservative treatment

Most cases of uncomplicated urolithiasis usually require conservative treatment. Considering a trial of conservative management is justified because ureteral dilation during this period allows stones to pass spontaneously more easily, especially when the stone is

singular, smaller than 10mm, and there are no signs of infection (Cretu et al., 2022). Spontaneous passage of the stone can occur in up to 70-80% of cases (Soffner Cardoso and Lopes Neto, 2022). Pregnant woman body undergoes many changes such as increased glomerular filtration rate (GFR) and hydronephrosis, are responsible for a higher rate of stone clearance in pregnant women (81%), compared to non-pregnant women (47%) (Soffner Cardoso and Lopes Neto, 2022) and the EAU have determined that healthy conservatives are the best management for patients with symptomatic hydronephrosis/ureteral stones when treated conservatively with analgesics, fluids, antiemetics, α -blockers, and antibiotics for any signs of sepsis (Chan et al 2023). For pain relief during all trimesters of pregnancy, paracetamol is the preferred medication. Anti-inflammatory and non-steroidal drugs can help manage symptoms during the first and second trimesters of pregnancy. However, you should avoid them in the third trimester because they increase the risk of fetal ductus arteriosus closure and persistent pulmonary hypertension. On the other hand, opioids should be used with particular caution up to the 30th week of pregnancy because they can cause respiratory depression in newborns (Chan et al., 2023).

The first-line management of nausea and vomiting treatment consists of antihistamine-based medications. Drugs such as promethazine, cyclizine, cinnarizine, doxylamine, and dimenhydrinate are safe throughout pregnancy. However, phenothiazines, including prochlorperazine, chlorpromazine, and perphenazine, although also recommended as first-line medications, may cause drug-induced extrapyramidal symptoms and oculogyric crises. Dopamine antagonists, including metoclopramide and domperidone, are recommended as second-line treatment for a maximum period of 5 days, but they may also cause side effects similar to those mentioned above. Ondansetron, a well-known antiemetic drug in the general population, can be used in pregnant women only when previously mentioned drugs fail, but not in the first trimester of pregnancy, and the safety data regarding its use are limited (Chan et al., 2023). α -Blockers (such as tamsulosin) are useful for Medical Expulsive Therapy (MET). They might not impact the pregnancy-related ureteral obstruction. Their efficacy is questionable. (Juliebø-Jones et al., 2022). Regarding antibiotics, penicillin or cephalosporins are allowed in pregnant women, as they have the fewest side effects for both fetal and maternal health. However, erythromycin, sulfonamides, nitrofurantoin, tetracyclines, chloramphenicol, aminoglycosides, and quinolones are contraindicated during pregnancy because they can cause fetal and maternal adverse effects (Juliebø-Jones et al., 2022; Dai et al., 2021). About 30% of those diagnosed will require some form of pain management through surgical intervention (Juliebø-Jones et al., 2022). It requires significant experience and knowledge on the part of physicians when deciding whether to continue a conservative management plan or whether patients may obtain sufficient benefit to warrant surgical interventions. Several factors strongly predict whether or not a patient would require surgical interventions: the length of pain (≥ 4 days); the amount of stone size (≥ 8 mm); having fever (>37.5 degrees Celsius); and the presence of hydronephrosis (mild 30mm or less; mod 30 & 40mm; sever ≥ 40 mm) (He et al., 2022).

Second path – surgical treatment

The key factors that must be taken into account when determining whether to proceed with a surgical procedure while pregnant include the potential pros and cons associated with that surgical procedure, as well as the health of both the mother and the fetus. Not completing an urgent and necessary surgical procedure (e.g., in cases of acute sepsis) may put the patient at an increased risk for obstetric complications, such as a preterm delivery. Doctors should consider surgical intervention if any of these symptoms are present: sepsis, pain (despite using medications), significant damage to the kidneys, or one kidney (Chan et al., 2023).

Indications for urgent surgical intervention also include recurrent vomiting, stones greater than 1 cm, bilateral ureteral obstruction, and obstetrical complications (Soffner Cardoso and Lopes Neto, 2022). The second trimester of pregnancy is the easiest time to carry out a non-obstetrical procedure. The first and third trimesters are both at risk for miscarriage and/or preterm delivery; therefore, no surgical interventions should occur until after the second trimester. The classification of available surgical treatments includes temporary procedures that relieve pressure on the urinary system (e.g., double-J stent or nephrostomy tube) or definitive procedures that treat the underlying cause (e.g., ureterorenoscopy (URS)) (Chan et al., 2023).

Double-J stent (DJ)

The purpose of the internal DJ stent is to provide temporary urine drainage in pregnant women with urolithiasis until delivery. Under cystoscopic guidance through the external urethral orifice, a small catheter is inserted into the renal pelvis. Its placement allows free flow of urine into the bladder despite the continuous presence of a stone in the urinary tract. The medical team can perform the procedure under any anesthesia in the lithotomy position, and they administer a prophylactic dose of antibiotics (Cretu et al., 2022).

There is evidence that insertion of a DJ stent seems to be more effective than conservative treatment in the management of symptomatic moderate-to-severe hydronephrosis during pregnancy (EAU Guidelines, 2024).

Unfortunately, the main drawback of this solution is that the DJ stent in pregnant women becomes significantly more prone to encrustation due to changes in urine composition in this patient group. It is recommended to replace them at least every 4-6 weeks, necessitating multiple hospitalizations until the end of pregnancy (Dai et al., 2021). However, serial stenting may be poorly tolerated by some pregnant women as it can cause pain and reduce their quality of life. Increased frequency of such invasive operations also leads to higher complication rates, including urinary track infections (UTIs) and stent migration, as well as higher hospitalization costs (Jin et al., 2022).

Percutaneous nephrostomy tube (PCN)

Surgeons insert a nephrostomy tube into the renal pelvis through the skin layers. Doctors successfully use it in pregnant women during the first trimester (Dai et al., 2021). However, studies have shown that complications of the procedure may occur, including nephrostomy tube blockage, dislodgment, or infection (Chan et al., 2023). The most common negative aspect of this solution, similar to the DJ stent, remains encrustation, necessitating replacement every 4-6 weeks at most, averaging 1.6 times per pregnancy, or every 21-33 days (Keenan et al., 2022). Comparing the use of a DJ stent to PCN, researchers observed no significant differences in adverse events related to pregnancy. The placement of DJ stents resulted in a lower rate of hospitalizations, emergency room visits, and other exchanges than nephrostomy tubes (European Association of Urology guidelines, 2024).

URS - definitive stone management

Medical professionals consider ureteroscopy a reasonable alternative to avoid long-term stenting or drainage, according to the latest EAU guidelines (EAU Guidelines, 2024). Doctors also choose it as the surgical procedure of choice for treating the cause of urolithiasis during pregnancy. Ureteroscopy does not require longer anesthesia time or fluoroscopy than a DJ stent, and it is associated with lower rates of premature birth. Studies have shown the safety of both mother and fetus, as well as an efficacy rate of 87% in treating urolithiasis (Soffner Cardoso and Lopes Neto, 2022). It is worth noting that this procedure is more cost-efficient than a ureteral stent at any stage of pregnancy (Wymer et al., 2015). It also resulted in fewer irritative LUTS and better patient satisfaction (EAU Guidelines, 2024).

Despite the ACOG recommendation to perform non-obstetric procedures in the second trimester of pregnancy, URS has also been successfully performed in both the first and third trimesters (Dai et al., 2021). Semirigid ureteroscopes can be used in both the first and second trimester of pregnancy to perform this procedure. In contrast, clinicians can use flexible ureteroscopes for this procedure in the third trimester of pregnancy. The preferred method for destroying stones is a Holmium: YAG laser, as it is the least damaging to the fetus among stone-destroying methods, including pneumatic lithotripsy (Cretu et al., 2022). In patients who have septic symptoms and have a blocked urinary tract, no physician should perform primary ureteroscopy. Instead, the clinician should insert a double-J stent or perform a nephrostomy to provide immediate decompression. Once the infection is over and the patient is stable, the clinician should reschedule definitive therapy with ureteral stenting (Keenan et al., 2022). Table 1 summarizes the diagnostic and treatment methods.

Table 1. Summary of diagnostic and treatment methods.

Category	Method	Key Findings & Safety
1st Line Imaging	UGS	Gold standard. Safe and widely available.
2nd Line Imaging	MRI/MRU	High sensitivity and specificity. Safe.
Last Resort Imaging	Low-Dose CT	Highest positive predictive value, but involves radiation.
Initial Treatment	Conservative Management	Success in 70-80% of cases. Includes hydration and pain relief. Paracetamol is preferred; avoid NSAIDs in the 3rd trimester.

Temporary Drainage	Double-J Stent/Nephrostomy	Relieves obstruction. Major drawback: high risk of encrustation in pregnancy; requires replacement every 4–6 weeks.
Definitive Treatment	Ureteroscopy (URS)	Highly effective. Safe in all trimesters. More cost-efficient and better patient satisfaction than long-term stenting.
Indications for surgery	Emergency Criteria	Sepsis, intractable pain, renal failure, stones >1cm, or failure of conservative treatment.

4. CONCLUSION

Diagnosing and treating pregnant women with urolithiasis is always a challenging and complex task. The therapeutic process requires collaboration among doctors from various specialties, as well as knowledge and experience. Choosing the appropriate course of action should be preceded by appropriate examinations tailored to the patient's health status and gestational age. Every caregiver should carefully consider every move and take actions efficiently to provide the best care for both the mother and the developing child. While initial conservative treatment is often effective, it may prove insufficient. The patient, obstetrician, and urologist should jointly decide on surgical treatment and discuss the advantages and disadvantages of each option. This work will help clarify the latest diagnostic and therapeutic pathways and improve the care of this narrow yet demanding patient group.

Acknowledgments

We thank all participants who contributed to the studies included in this systematic review. We also acknowledge the support of our institution and colleagues who guided manuscript preparation.

Authors' Contributions

Conceptualization, supervision, and project administration: Gabriela Krych, Bartłomiej Kazimierski, Weronika Gniado.

Methodology: Michał Skóra, Klaudia Jadczak.

Software, validation, formal analysis, investigation, resources, writing original draft preparation: Weronika Gniado, Aleksandra Rusak, Dawid Mądry.

Writing, review editing, and visualization: Gabriela Krych, Bartłomiej Kazimierski.

All authors have read and agreed with the published version of the manuscript.

Informed consent

Not applicable.

Ethical approval

Not applicable. This article does not contain any studies with human participants or animals performed by any of the authors.

Funding

This research did not receive any external funding like specific grant from funding agencies in the public, commercial, or nonprofit sectors.

Conflict of interest

The authors declare that they have no conflicts of interest, competing financial interests or personal relationships that could have influenced the work reported in this paper.

Data and materials availability

All data associated with this study will be available based on the reasonable request to corresponding author.

REFERENCES

- American College of Obstetricians and Gynecologists. Guidelines for Diagnostic Imaging During Pregnancy and Lactation. Committee Opinion No. 723. *Obstet Gynecol* 2017;130(4):e210–16.
- Bold MS, Boyum JH, Potretzke AM, Rose CH, Atwell TD, Sviggum EB, Goss BC, Brown DL. Detection of distal ureteral stones in pregnancy using transvaginal ultrasound. *J Ultrasound* 2021;24(2):161–6.
- Chan K, Shakir T, El-Taji O, Patel AR, Bycroft J, Lim CP, Vasdev N. Management of urolithiasis in pregnancy. *Curr Urol* 2023;17(1):1–6.
- Clements HA, Duncan KR, Fielding K, Gowland PA, Johnson IT, Baker PN. Infants exposed to MRI in utero have a normal pediatric assessment at 9 months of age. *Br J Radiol* 2000; 73(866):190–4.
- Cretu M, Ciobanu AM, Gica C, Demetrian M, Cimpoia-Raptis BA, Peltecu G, Botezatu R, Gica N, Panaitescu AM. Urolithiasis – a challenge during pregnancy. *Rom Med J* 2022; 69(S2):82–7.
- Dai JC, Nicholson TM, Chang HC, Desai AC, Sweet RM, Harper JD, Sorensen MD. Nephrolithiasis in Pregnancy: Treating for Two. *Urology* 2021;151:44–53.
- European Association of Urology. EAU Guidelines on Urolithiasis [Internet]. Arnheim: EAU Guidelines Office; 2024 <https://uroweb.org/guidelines/urolithiasis>
- He M, Lin X, Lei M, Xu X, He Z. The identification of pregnant women with renal colic who may need surgical intervention. *BMC Urol* 2022;22(1):31.
- Jin X, Liu B, Xiong Y, Wang Y, Tu W, Shao Y, Zhang L, Wang D. Outcomes of ureteroscopy and internal ureteral stent for pregnancy with urolithiasis: a systematic review and meta-analysis. *BMC Urol* 2022;22(1):150.
- Juliebø-Jones P, Somani BK, Baug S, Beisland C, Ulvik Ø. Management of Kidney Stone Disease in Pregnancy: A Practical and Evidence-Based Approach. *Curr Urol Rep* 2022; 23(11):263–70.
- Keenan RA, Hegarty NJ, Davis NF. Symptomatic Hydronephrosis and Ureteral Calculi in Pregnancy: A Narrative Review with a Proposed Management Protocol. *J Endourol* 2022;36(8):1099–112.
- N'gamba M, Lebdaï S, Hasting C, Panayotopoulos P, Ammi M, Sentilhes L, Descamps P, Azzouzi AR, Bigot P. Acute renal colic during pregnancy: management and predictive factors. *Can J Urol* 2015;22(2):7732–8.
- Radu VD, Vasilache IA, Costache RC, Scripcariu IS, Nemescu D, Carauleanu A, Nachi-for V, Groza V, Onofrei P, Boiculescu L, Socolov D. Pregnancy Outcomes in a Cohort of Patients Who Underwent Double-J Ureteric Stenting—A Single Center Experience. *Me-dicina (Kaunas)* 2022;58(5):619.
- Salehi-Pourmehr H, Tayebi S, DalirAkbari N, Ghabousian A, Tahmasbi F, Rahmati F, Naseri A, Hajebrahimi R, Mehdipour R, Hemmati-Ghavshough M, Mostafaei A, Hajeb-rahimi S. Management of urolithiasis in pregnancy: A systematic review and meta-analysis. *Scand J Surg* 2023;112(2):105–16.
- Soffner Cardoso PA, Lopes Neto AC. Update on approaches to urinary lithiasis in pregnancy. *Ital J Gynaecol Obstet* 2022;34(02):103–10.
- Wymer K, Plunkett BA, Park S. Urolithiasis in pregnancy: a cost-effectiveness analysis of ureteroscopic management vs ureteral stenting. *Am J Obstet Gynecol* 2015;213(5):691.e1–8.