

Medical Science

To Cite:

Almajed M, Albarrak Y, Aldosari W, Alkhormi M, Alawfi A, Islam H. Post corrosive ingestion in pediatrics; precaution and awareness; retrospective hospital-based study. *Medical Science* 2024; 28: e15ms3295 doi:

Authors' Affiliation:

¹Pediatric Gastroenterology Consultant, First Health cluster, Pediatric Hospital, King Saud Medical City, Riyadh, Saudi Arabia
²Pediatric Gastroenterology Fellow, First Health cluster, Pediatric Hospital, King Saud Medical City, Riyadh, Saudi Arabia

Peer-Review History

Received: 29 December 2023

Reviewed & Revised: 02/January/2024 to 29/February/2024

Accepted: 04 March 2024

Published: 11 March 2024

Peer-review Method

External peer-review was done through double-blind method.

Medical Science

pISSN 2321-7359; eISSN 2321-7367



© The Author(s) 2024. Open Access. This article is licensed under a [Creative Commons Attribution License 4.0 \(CC BY 4.0\)](https://creativecommons.org/licenses/by/4.0/), which permits use, sharing, adaptation, distribution and reproduction in any medium or format, as long as you give appropriate credit to the original author(s) and the source, provide a link to the Creative Commons license, and indicate if changes were made. To view a copy of this license, visit <http://creativecommons.org/licenses/by/4.0/>.

Post corrosive ingestion in pediatrics; precaution and awareness; retrospective hospital-based study

Muhannad Almajed¹, Yasir Albarrak², Wadha Aldosari¹,
Musa Alkhormi¹, Ahmed Alawfi¹, Husam Islam¹

ABSTRACT

Background: Both acidic and alkaline products that are corrosive when ingested might result in major complications. This research focused on pediatric patients, including males up to 12 years old and females up to 14 years old, who had a history of corrosive ingestion and needed an upper endoscopy as part of their assessment. **Method:** This study involved a retrospective analysis of pediatric patients diagnosed with Post corrosive ingestion at Gastroenterology department in Children's Hospital, King Saud Medical City, Riyadh, Saudi Arabia. The analysis covered a seven-year period from 2015 to 2022. The research population consisted of 57 pediatric patients who underwent endoscopic examination of corrosive intake after presenting with corrosive ingestion. **Results:** We included 69 pediatric patients with corrosive ingestion. Mean patient age was 37.2 ± 31.5 , (59.4%) were male. Corrosive ingestion was alkali in 44 subject (63.8%). Regarding patient's symptoms, the most prevalent symptom was vomiting 53.6% and 10.1% of patients were a symptomatic. The majority of patients 43.5% has no signs at presentation, 37.7% had swelling, 26.1% erythema and 21.7% had ulcer. Regarding endoscopic findings 50.7% of patients found to be grade 0 esophageal injury. No statistically significant difference was detected between endoscopy findings and type of corrosive ingested. Most of the cases (92.7%) were reported with no complications. **Conclusion:** According to this study, corrosive damage still ranks highly among pediatric emergencies and presents a significant risk of sequelae, mostly stricture.

Keywords: Corrosive ingestion, pediatric, GI endoscopy

1. INTRODUCTION

Corrosive substances are chemicals that cause destruction or damage to living tissue on contact by dissolving or deteriorating a living tissue such as surface of

the skin; Common corrosives could be acids (such as sulfuric acids, nitric acid, hydrochloric acid etc.), or bases (such as potassium hydroxide, sodium hydroxide etc.) (Hugh and Kelly, 1999). Corrosive ingestion is a common emergency presentation that can be noticed and dealt with; such cases are still coming despite the increasing of awareness (Lee et al., 2010). The consequences of corrosives are wide spectrum ranging from asymptomatic presentation to serious presentation and complication especially if PH less than 2 or more than 12 (Poley et al., 2004; Mamede and De-Mello-Filho, 2002). Stricture it considers as short-term complication, but obstruction perforation and cancer risk are long term complication. Most common ingested agents were household chemicals, such as detergents and bleaches (Stiff et al., 1996). House kitchen major source of these product and contain more than 500 toxic substances (Rafeey et al., 2016).

Pediatrics are the most exposed subjects to corrosives due to unawareness or unaware about the utilization of the protective equipment. Pediatrics were identified according to the KSMC policy if the boys/male below 13yrs and girls/female below 15yrs. In study at the Southwestern region of Saudi Arabia, they found the mean age of the pediatric patients with corrosive ingestion was 28 ± 20 months (Al-Binali et al., 2009). It had been suggested that looking inside the body “using endoscopy procedure” to be standard of care to examine the upper part of the gastrointestinal tract in case of any corrosive ingestion. In United States, the incidence is 15.8 cases in every 100,000 persons (Arévalo-Silva et al., 2006). The oral lesion finding usually do not correlate with severity of esophagus injury. So, it cannot depend one examination or history without extended workup (Hijazeen, 1998).

As know that accidental ingestion the main cause for pediatric patient but still the suicidal attempt one of the possible causes for ingestion (Di-Nardo et al., 2020). Caustic soda, ammonium chloride, and lipid dissolver consumption were the most frequent causes of stricture formation in Indians as a result of corrosive material eating (Karaman et al., 2015). The study population include all pediatric patient with history of corrosive ingestion who undergone upper GI endoscopy as part from their management at King Saud Medical City (KSMC) which considered the largest tertiary care in Saudi Arabia and most corrosive cases reported to the emergency of KSMC. This study will cover all aspects of corrosive cases in terms of patients’ description, type of corrosive, presenting symptoms, signs, endoscopy finding, and complication.

2. METHOD

This study involved a retrospective analysis of pediatric patients diagnosed with Post corrosive ingestion at Gastroenterology department in Children’s Hospital, King Saud Medical City, Riyadh, Saudi Arabia. The analysis covered a seven-year period from 2015 to 2022. The research population consisted of 57 individuals who underwent endoscopic examination of corrosive intake after presenting with corrosive ingestion. This study focused on pediatric patients—males up to 12 years and females up to the age of 14—who had a history of ingesting caustic material and required an upper endoscopy as part of their management. Data were gathered using a self-created formula using demographic information such as age, gender, and kind of corrosive consumed, the data collection form was checked by a consultant study supervisor.

Symptoms and signs were also recorded additional to endoscopic findings of esophageal injuries were classified depending on the depth and extent of burns into; Normal esophagus= Grade 0, hyperemia and Mucosal edema= Grade I, Friability, hemorrhage, erosions, exudates, blisters, whitish membrane and shallow ulcers= Grade II a, deep or circumferential lesions additional to Grade II lesions= Grade II b, Small or scattered areas of necrosis= Grade III a, Extensive necrosis= Grade III b (Uygun, 2015). The study excluded patients whose esophageal damage was not caused by ingesting acid or alkali. Using SPSS Version 24, a descriptive analysis of the research variables was carried out. Frequency and percentage were used for categorical variables and mean with standard deviation were used for continuous variables. A p-value of less than 0.05 was deemed statistically significant when the Chi-square test was employed. Ethical approval was obtained from King Saud medical city ethical review board.

3. RESULTS

We included 69 pediatric patients with corrosive ingestion. Mean patient age was 37.2 ± 31.5 , 41 subjects (59.4%) were male and 28 (40.6%) were female. Corrosive ingestion was classified in the study to alkali ingestion, 44 subject (63.8%) and acidic, 25 subject (36.2%) (Table 1). Regarding patient’s symptoms, the most prevalent symptom was vomiting 53.6% (26 alkaline, 11 acid), pain 29% (11 alkaline, 9 acid), Drooling 27.5% (11 alkaline, 8 acid), respiratory symptoms 27.5% (11 alkaline, 8 acid), and dysphagia 11.6% (7 alkaline, 1 acid) of patients, while 10.1% (5 alkaline, 2 acid) of patients were a symptomatic (Table 2; Figure 1), no statistically significant difference was

detected between symptoms and type of corrosive ingested. The majority of patients 43.5% (20 alkaline, 10 acid), has no signs at presentation, 37.7% (17 alkaline, 9 acid), had swelling, 26.1% (11 alkaline, 7 acid), erythema and 21.7% (11 alkaline, 4 acid), had ulcer.

No statistically significant difference was detected between signs and type of corrosive ingested. Regarding endoscopic findings of esophageal injury 35 (21 alkaline, 14 acid), of patients found to have grade 0, 23 (15 alkaline, 8 acid) grade 1, 13 (9 alkaline, 4 acid) grade 2a, 5 (1 alkaline, 4 acid) grade 2b, 4 (2 alkaline, 2 acid) grade 3a, while no grade 3b or grade 4 was identified. No statistically significant difference was detected between endoscopy findings and type of corrosive ingested. Most of the cases (92.7%) were reported with no complications, 7.2% were reported with strictures and 2.8% of cases with obstructions, while results showed no perforation was reported. Obviously with minor complications, the result showed that only 2 patients needed single follow up, and one need follow up twice additional to 3 patients who need follow up more than 2 time, while 89.8% of patients don't need follow up.

Table 1 Frequency and descriptive statistics of demographics characteristics and (Symptoms & signs)

Variable	Frequency	Percent (%)
Age in months (Mean \pm SD)	37.2 \pm 31.5	
Gender		
Female	28	40.6
Male	41	59.4
Type of corrosive		
Alkaline	44	63.8
Acid	25	36.2
Symptoms		
Dysphagia	8	11.6
Pain	20	29
Vomiting	37	53.6
Drooling	19	27.5
Respiratory symptoms	19	27.5
Asymptomatic	7	10.1
Signs		
Erythema	18	26.1
Swellings	26	37.7
Ulcer	15	21.7
No signs	30	43.5

Table 2 Chi square with Pearson correlations test for Type of corrosive and (symptoms & signs)

		Type of corrosive		Total	P value
		Alkaline	Acid		
Symptoms					
Dysphagia	No	37	24	61	0.137
	Yes	7	1	8	
Pain	No	33	16	49	0.333
	Yes	11	9	20	
Vomiting	No	18	14	32	0.227
	Yes	26	11	37	
Drooling	No	33	17	50	0.532
	Yes	11	8	19	
Respiratory	No	33	17	50	0.529

symptoms	Yes	11	8	19	
Asymptomatic	No	39	23	62	0.656
	Yes	5	2	7	
Signs					
Erythema	No	33	18	51	0.785
	Yes	11	7	18	
Swellings	No	27	16	43	0.828
	Yes	17	9	26	
Ulcer	No	33	21	54	0.384
	Yes	11	4	15	
No signs	No	24	15	39	0.660
	Yes	20	10	30	
Endoscopy findings					
Grade 0	No	23	11	34	0.509
	Yes	21	14	35	
Grade 1	No	29	17	46	0.859
	Yes	15	8	23	
Grade 2a	No	35	21	56	0.649
	Yes	9	4	13	
Grade 2b	No	34	21	64	0.035
	Yes	1	4	5	
Grade 3a	No	42	23	65	0.555
	Yes	2	2	4	
Grade 3b	No	44	25	69	
Grade 4	No	44	25	69	
Complications					
Stricture	No	42	22	64	0.251
	Yes	2	3	5	
Obstruction	No	43	24	67	0.681
	Yes	1	1	2	
Perforation	No	44	25	69	
No complication	No	2	3	5	0.251
	Yes	42	22	64	

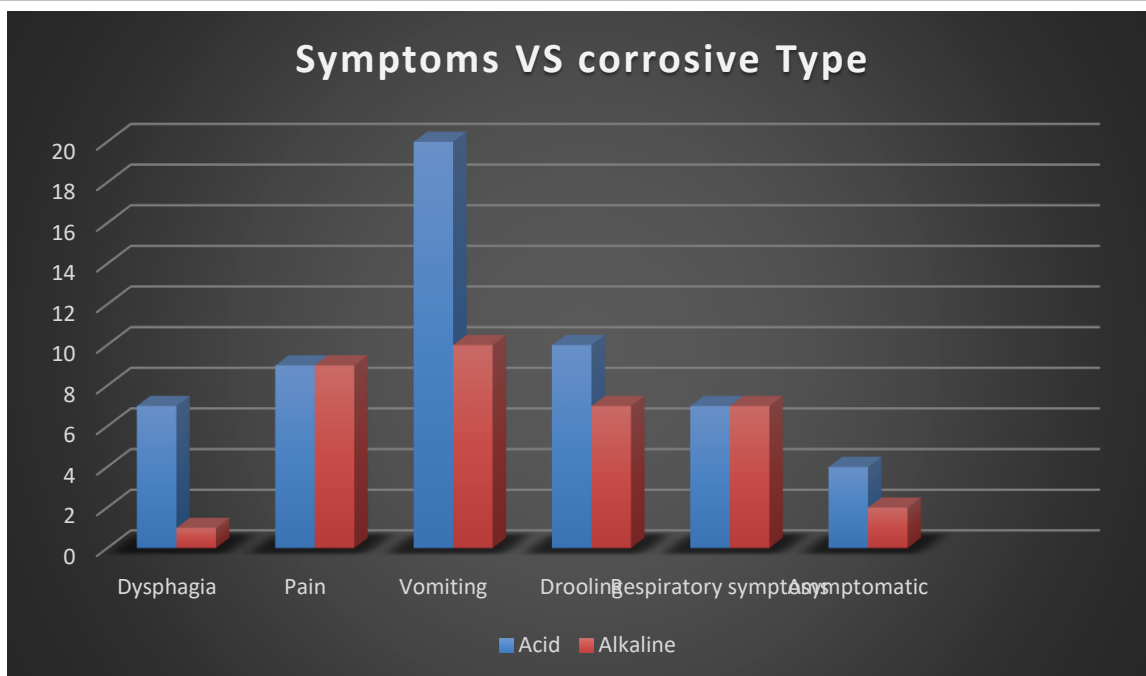


Figure 1 Symptoms VS corrosive Type

4. DISCUSSION

Gastrointestinal tract injuries resulting from caustic ingestion are a global emergency concern for children. The greatest age group at risk for inadvertent corrosive intake is children under five, with a two-year-old being the most vulnerable. Youngsters at this age are adept at finding and consuming liquids, but they are not able to distinguish between harmful and edible liquids (Al-Binali et al., 2009). This age group's natural curiosity, their capacity to reach higher places and handle riskier goods, their carers' carelessness, and the custom of storing caustic substances in beverage bottles are all factors that contribute to these kinds of mishaps (Di-Nardo et al., 2020). In our study, the characteristic of corrosive ingestion was studied on a total of 69 pediatric patients, with a mean age of 37.2 ± 31.5 , with majority of male. Which also presented in the other studies with predominant male gender and age below 5 years (Stiff et al., 1996; Al-Binali et al., 2009; Di-Nardo et al., 2020).

Corrosive ingestion can be classified to acid or alkaline depends on PH level, Acid with PH less than 3 cause coagulation necrosis on tissue contact and it is well known that acids tend to destroy the stomach and spare the esophagus. This is caused by the squamous epithelium's relative resistance to acid damage, the brief contact period brought on by the acid's quick passage down the oesophagus, and pyloric spasm. Acid injuries more frequently result in antral stenosis in the stomach's antrum. Conversely, alkaline materials with a PH of more than 9 cause liquefaction necrosis, which dissolves collagen and protein and usually results in strictures and burns to the esophagus. It can also infrequently cause stomach damage (Hugh and Kelly, 1999). Most of the previous studies Karaman et al., (2015), Di-Nardo et al., (2020) presenting with alkaline substance which more common like our study 63.8% of cases were alkaline ingestion. Although alkaline substance more common, there are some studies found acids ingestion is the most common associated with esophagus and stomach damage (Hugh and Kelly, 1999; Hijazeen, 1998).

There were variety of presentation between asymptomatic to symptomatic presented with one or more symptoms (dysphagia, pain, vomiting, drooling, respiratory symptoms) as well as signs (swellings, erythema, and ulcer). In our study, 89.1% of patients were symptomatic, common initial presenting symptoms were were vomiting, pain, Drooling, respiratory symptoms and dysphagia. The most signs were oral cavity swelling, oral ulcer and erythema, both symptoms and signs were similar to other study Stiff et al., (1996) study. Since endoscopy may often detect an esophageal burn without causing oral injuries, it is the most effective method of determining the exact amount and degree of injury. When the patient's condition has stabilized, endoscopy need to be carried out as soon as possible, ideally within 48 hours of ingestion, when the lumen is still at its strongest (Hugh and Kelly, 1999).

The prediction of esophageal injury from signs and symptoms and the need for upper gastrointestinal endoscopy have been discussed in earlier publications, with varying degrees of success. While some may only utilize esophagoscopy for individuals who have consumed powerful corrosive chemicals or who exhibit obvious symptoms, we routinely conducted it for all patients presenting with corrosive substance ingestion. Significant lesions at endoscopy are unusual when symptoms are absent after inadvertently ingesting small amounts of less aggressive substances, despite the fact that severe esophageal injuries have been reported in 12% to 26% of asymptomatic children. According to this, endoscopy may not be required in asymptomatic patients following accidental caustic ingestion, particularly if the patient does not exhibit oropharyngeal burns and the ingestion is just suspected (Karaman et al., 2015; Di-Nardo et al., 2020).

We would not recommend endoscopy if referral is made between 2 and 14 days since the oesophagus is at risk of perforation; however, others believe that the time after ingestion is immaterial and advocate endoscopy in all cases (Mamede and De-Mello-Filho, 2002). The process of injury and healing after ingestion of alkali may be divided into three phases. The first is damage to tissues by a process of liquefactive necrosis with saponification of all layers of the oesophagus wall. From 5 to 14 days, necrotic tissue resulting from vascular thrombosis begins to slough and the oedema occurring as part of the inflammatory reaction is also at a maximum, thus the oesophagus is at its weakest. The third stage occurs between 2 weeks and 3 months. During this phase the collagen deposited as part of the healing process contracts leading to stricture formation. It is now that individuals begin to report symptoms of dysphagia and are referred for investigation (Stiff et al., 1996). Most of patients were found to be grade 0. The high grades (such as 3b and 4) were not detected in our sample.

Most of the cases were reported with no complications and results showed no perforation was reported. The outcome in patients ingesting corrosive substances is quite variable, most of cases from other study had higher number finding from grade 1 to 3a, with less frequent 3b or 4, that explained by patient ingested unintentionally with small amount (Hijazeen, 1998). Esophageal stricture is the most common ingestion-related consequence. According to reports, the percentage of stricture development varies from 2% to 63% Karaman et al., (2015), Di-Nardo et al., (2020), and it was 7% in our case. According to the majority of research, patients who have mucosal damage that is more severe than grade 2a are more likely to experience major difficulties, whereas individuals who just have minor mucosal damage have far lower rates of death and morbidity (Mamede and De-Mello-Filho, 2002).

5. CONCLUSION

This study indicates that corrosive injury continues to be one of the most common paediatric crises and has a high risk of sequelae, mostly stricture. A nationwide campaign is needed to increase public awareness of the negative effects of caustic agents, the benefits of creating agents that are less concentrated, and the appropriate handling techniques, especially after consumption.

Ethical approval

Ethical approval was obtained from King Saud medical city ethical review board. The ethical guidelines for Human Subjects are followed in the study.

Funding

This study has not received any external funding.

Conflict of interest

The authors declare that there is no conflict of interests.

Data and materials availability

All data sets collected during this study are available upon reasonable request from the corresponding author.

REFERENCES

1. Al-Binali AM, Al-Shehri MA, Abdelmoneim I, Shomrani AS, Al-Fifi SH. Pattern of corrosive ingestion in southwestern Saudi Arabia. *Saudi J Gastroenterol* 2009; 15(1):15-7. doi: 10.4103/1319-3767.41744

2. Arévalo-Silva C, Eliashar R, Wohlgelernter J, Elidan J, Gross M. Ingestion of caustic substances: a 15-year experience. *Laryngoscope* 2006; 116(8):1422–6. doi: 10.1097/01.mlg.0000225376.83670.4d
3. Di-Nardo G, Betalli P, Illiceto MT, Giulia G, Martemucci L, Caruso F, Lisi G, Romano G, Villa MP, Ziparo C, Pensabene L, Vassallo F, Quitadamo P. Caustic Ingestion in Children: 1 Year Experience in 3 Italian Referral Centers. *J Pediatr Gastroenterol Nutr* 2020; 71(1):19-22. doi: 10.1097/MPG.0000000000002685
4. Hijazeen R. Corrosive burns of the upper gastrointestinal tract among Jordanian children. *Ann Saudi Med* 1998; 18(2):173-5. doi: 10.5144/0256-4947.1998.173
5. Hugh B, Kelly MD. Michael Corrosive ingestion and the surgeon. *J Am Coll Surg* 1999; 189(5):508–22. doi: 10.1016/S1072-7515(99)00160-X
6. Karaman İ, Koç O, Karaman A, Erdoğan D, Çavuşoğlu YH, Afşarlar ÇE, Yilmaz E, Ertürk A, Balci Ö, Özgüner İF. Evaluation of 968 children with corrosive substance ingestion. *Indian J Crit Care Med* 2015; 19(12):714-8. doi: 10.4103/0972-5229.171377
7. Lee HJ, Lee JH, Seo JM, Lee SK, Choe YH. A single center experience of self-bougienage on stricture recurrence after surgery for corrosive esophageal strictures in children. *Yonsei Med J* 2010; 51(2):202–5. doi: 10.3349/ymj.2010.51.2.202
8. Mamede R, De-Mello-Filho F. Treatment of caustic ingestion: an analysis of 239 cases. *Dis Esophagus* 2002; 15(3):210–3. doi: 10.1046/j.1442-2050.2002.00263.x
9. Poley JW, Steyerberg EW, Kuipers EJ, Dees J, Hartmans R, Tilanus HW, Siersema PD. Ingestion of acid and alkaline agents: outcome and prognostic value of early upper endoscopy. *Gastrointest Endosc* 2004; 60(3):372-7. doi: 10.1016/S0016-5107(04)01722-5
10. Rafeey M, Ghajazadeh M, Sheikhi S, Vahedi L. Caustic Ingestion in Children: a Systematic Review and Meta-Analysis. *J Caring Sci* 2016; 5(3):251-265. doi: 10.15171/jcs.2016.027
11. Stiff G, Alwafi A, Rees BL, Lari J. Corrosive injuries of the oesophagus and stomach: experience in management at a regional paediatric centre. *Ann R Coll Surg Engl* 1996; 78(2):19-23.
12. Uygun I. Caustic oesophagitis in children: prevalence, the corrosive agents involved, and management from primary care through to surgery. *Curr Opin Otolaryngol Head Neck Surg* 2015; 23(6):423-32. doi: 10.1097/MOO.0000000000000198