

## Medical Science

### To Cite:

Pham PV, Tran HT, Nguyen DHN, Nguyen TDA, Duong LB. Gangrene sigmoid volvulus: A rare case report from Vietnam. *Medical Science* 2024; 28: e10ms3297  
doi:

### Authors' Affiliation:

<sup>1</sup>Department of Gastrointestinal Surgery, Binh Dan Hospital, Ho Chi Minh City, Vietnam

<sup>2</sup>Department of General Surgery, Pham Ngoc Thach Medical University, Ho Chi Minh City, Vietnam

### Peer-Review History

Received: 08 December 2023

Reviewed & Revised: 12/December/2023 to 23/February/2024

Accepted: 27 February 2024

Published: 02 March 2024

### Peer-review Method

External peer-review was done through double-blind method.

Medical Science

pISSN 2321-7359; eISSN 2321-7367



© The Author(s) 2024. Open Access. This article is licensed under a [Creative Commons Attribution License 4.0 \(CC BY 4.0\)](https://creativecommons.org/licenses/by/4.0/), which permits use, sharing, adaptation, distribution and reproduction in any medium or format, as long as you give appropriate credit to the original author(s) and the source, provide a link to the Creative Commons license, and indicate if changes were made. To view a copy of this license, visit <http://creativecommons.org/licenses/by/4.0/>.

# Gangrene sigmoid volvulus: A rare case report from Vietnam

Phu V Pham<sup>1</sup>, Hoa T Tran<sup>1,2</sup>, Duy HN Nguyen<sup>2</sup>, Truong DA Nguyen<sup>2</sup>, Lap B Duong<sup>1</sup>

## ABSTRACT

**Background:** Sigmoid volvulus is a gastrointestinal condition and a medical emergency that occurs when a segment of the colon twists upon its mesentery, leading to bowel obstruction and gangrene of the intestine. Male patients and seniors with persistent constipation are the primary populations affected by this condition. We present a rare case of a gangrene sigmoid volvulus diagnosed timely by CT-Scan. **Case presentation:** A 72-year-old Vietnamese male with a 3-day history of abdominal pain presented at the emergency department. A thorough medical history and physical examination revealed signs of bowel obstruction without evidence of peritonitis. Computed CT confirmed the diagnosis of sigmoid volvulus; it also led the surgical team to the decision to conduct an emergency laparotomy surgery due to the sigmoid ischemic sign depicted on the CT scan. **Conclusion:** This case report emphasizes the importance of radiographic tests in diagnosing and treating bowel obstruction. Especially in suspicion of volvulus, even without signs of peritonitis.

**Keywords:** Sigmoid volvulus, Hartmann's procedure, bowel ischemia

## 1. INTRODUCTION

The incidence of sigmoid volvulus is from 2% to 5% of colonic obstruction in Western countries and 20-50% in Eastern countries, according to recent data (Raveenthiran et al., 2010; Lal et al., 2006; Madiba et al., 1997). Sigmoid volvulus accounts for 9.2% of all cases of colonic obstruction. It is common in adults over 70 (Halabi et al., 2014). The cause of the sigmoid volvulus has yet to be fully understood. Numerous disorders can lead to sigmoid volvulus, including inflammation of the pelvis, adhesions around the sigmoid colon, and the setting of persistent constipation. The main symptoms are abdominal pain, constipation, and nausea. On physical examination, the abdomen is distended and tender. Plain abdominal X-ray radiographs show a dilated sigmoid colon and multiple air-fluid levels in the intestine. Abdominal CT scan shows a dilated bowel, a whirled sigmoid mesentery, or signs of bowel ischemia, as shown in this case report.

*Colon volvulus* is an emergency disease that needs to be detected promptly. If left untreated, the disorder quickly progresses to obstruction and colon gangrene, which can lead to electrolyte imbalances or septic shock. The overall mortality is 10% to 50%, while the overall morbidity is 6% to 24%. The sigmoidoscopy is the first treatment to decompress the sigmoid colon and restore the luminal flow. However, emergency surgery is necessary for patients presenting with bowel gangrene signs. We present a case of a 72-year-old Vietnamese male who underwent an emergency laparotomy due to gangrene sigmoid volvulus. Early recognition and timely surgical treatment reduce mortality and morbidity.

## 2. CASE PRESENTATION

A 72-year-old male presented at the emergency department with a three-day history of colicky pain localized around the periumbilical region, accompanied by abdominal distension and inability to pass stool and flatus. The patient had no other symptoms, such as fever, nausea, or rectal bleeding. There was also no history of chronic illness or allergies to drugs or foods.

The vital signs in the emergency room were as follows:

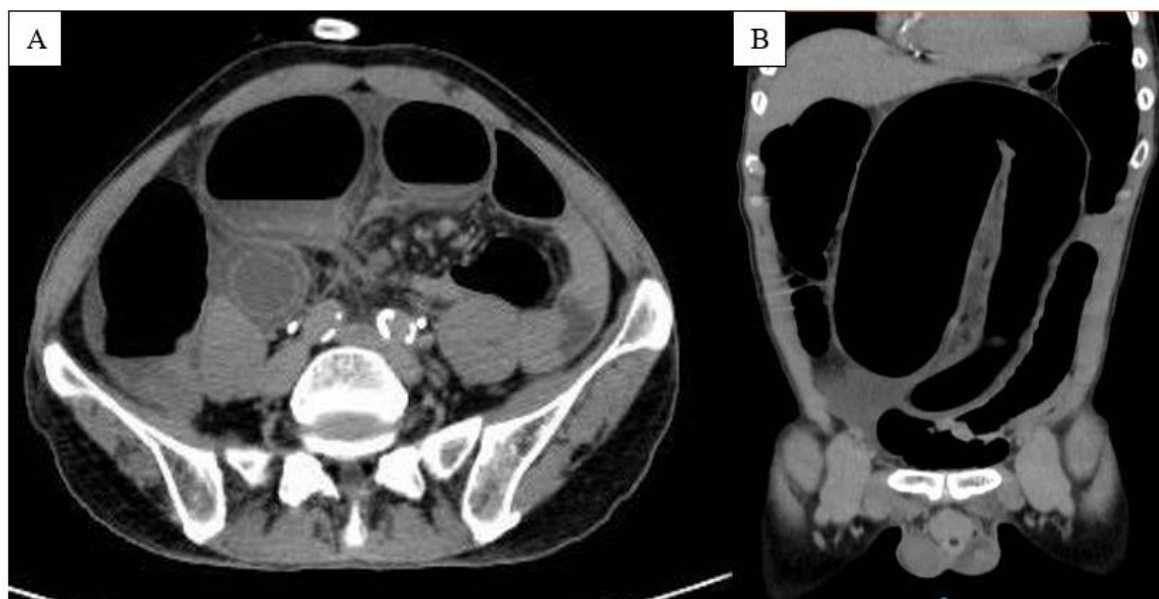
Pulse: 99 times/minute.

Temperature: 37°C.

Blood pressure: 100/70 mmHg.

Respiratory rate: 18 times per minute.

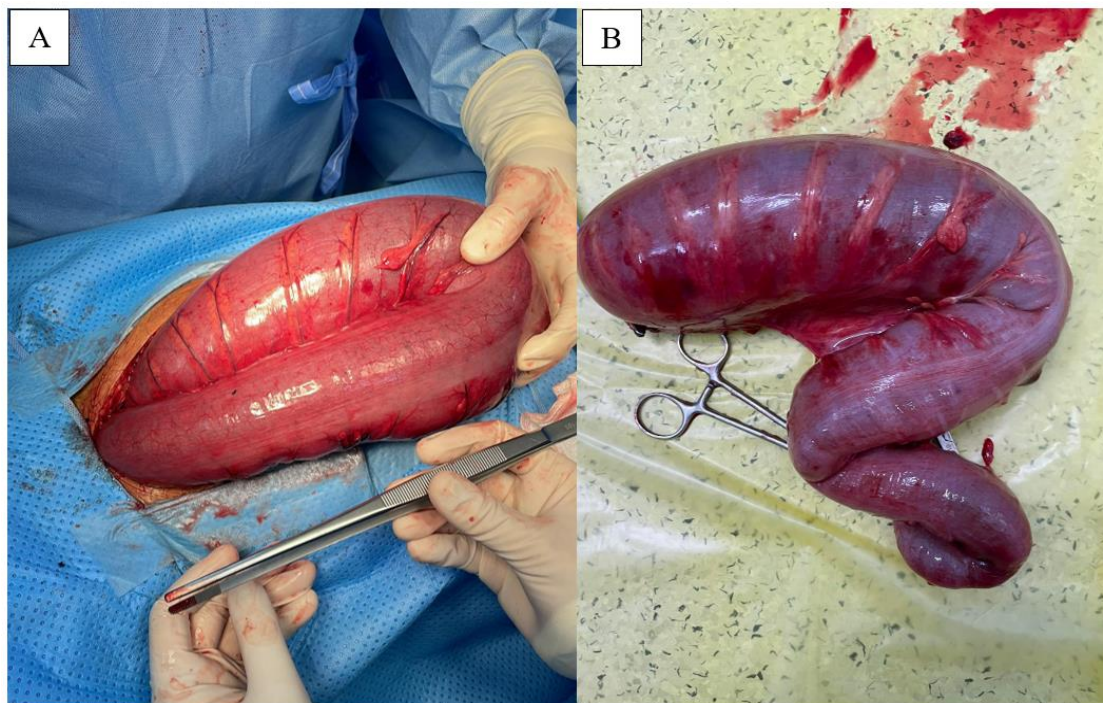
Clinical examinations revealed a sickly and dehydrated appearance. Abdominal examination revealed distension remarkably in the hypogastric region, tympanic, with no sign of peritonitis. A digital rectal examination noted the empty rectum with no stool nor blood on the examining finger, and the anal sphincter was normal in tone. Laboratory tests showed leukocytosis as WBC was 11.18 K/ $\mu$ L (%Neu: 89.4%), hyponatremia with normal renal function test. A plain radiograph indicated the feature of bowel obstruction. The ultrasonography indicated bowel distension with hyperactive peristalsis. The computed tomography revealed a substantial intestinal closed-loop blockage; the caecum dilated up to 67 mm distally to the sigmoid colon, and the colonic region was the location of the transition point (Figure 1). The obstructed colonic wall was hypoattenuating with the contrast agent, which raised the suspicion of colonic ischemia.



**Figure 1** CT scan of the patient's sigmoid volvulus. A: Horizontal plane with air-fluid levels; B: Frontal plane with coffee bean sign

The diagnosis was volvulus sigmoid with closed-loop blockage. Prior to the emergency laparotomy, the patient received intravenous fluid resuscitation and antibiotics. Intraoperatively, the edematous sigmoid colon twisted on its mesenteric pedicle and dilated up to 10 cm in diameter, and 40 cm of sigmoid colon was ischemic despite manually untwisting. We resected the ischemic

bowel and performed a Hartmann's procedure for later safety anastomosis (Figure 2). Postoperatively, the patient recovered well and had a good bowel movement on the third postoperative day; the colostomy worked well with no signs of ischemia. After surgery, there was no abnormality recorded. On the seventh day following surgery, the patient was discharged. The removed colon underwent histopathology, which revealed gangrenous bowel tissues.



**Figure 2** Volvulus Sigmoid colon. A: During laparotomy; B: After Hartmann's procedure

### 3. DISCUSSION

Colonic volvulus most frequently occurs in the sigmoid colon. The age at presentation is usually over 70 years of age, and there is a 2:1 male-to-female ratio. Sigmoid volvulus is more common in areas where a high-fiber diet is prevalent, such as Africa, India, and the Middle East. Institutionalized patients and those with disability via neurologic and psychiatric disorders experience higher rates (Halabi et al., 2014; Mangiante et al., 1989; Baker et al., 1994). Sigmoid volvulus causes a close-loop colon obstruction, manifesting as a sluggish, sneaky start of nausea, constipation, abdominal discomfort, and distention. Vascular compromise and rapid colonic dilatation occur when the twisting continues or worsens, which may result in necrosis and perforation (Ballantyne et al., 1985; Oren et al., 2007). The senior population may have less clinically apparent symptoms. A dilated sigmoid colon with the apex of the bend pointing toward the right upper quadrant is a typical radiography finding in 60% of the cases.

CT scan is necessary if a plain film is inconclusive. The coffee bean sign, the appropriately located X-marks-the-spot sign, the split-wall sign, the whirl sign, and the absence of rectal gas are all clues to a sigmoid volvulus. Treatments aim to reduce the twisted bowel and prevent a recurrence. An urgent operation is necessary if peritonitis, sepsis, gangrene, or bowel perforation is suspected based on clinical examination, laboratory results, and imaging investigations or discovered during an endoscopic evaluation. There have been descriptions of both open and laparoscopic techniques, with the latter being increasingly popular. A lower midline laparotomy is suitable to approach open resection. Following mobilization, the colon can be exteriorized through the laparotomy incision or a wound protector in situations requiring laparoscopic surgery.

The remaining are covered with towels to prevent contamination. The most reliable method of preventing recurrent volvulus is to conduct a sigmoid colectomy with colorectal anastomosis. Ostomy creation (either Hartmann's procedure with end-colostomy or a primary anastomosis with a diverting loop ileostomy) is uncommon in non-emergent cases. However, it may be necessary in the case of a deteriorating clinical picture, significant colonic distension, fecal spoilage, insufficient length, compromised blood supply, or

significant comorbidities that could predispose a patient to anastomotic breakdown (Raveenthiran et al., 2010; Oren et al., 2007; Arnold and Nance, 1973). The results of sigmoid volvulus with necrosis are generally poor. An emergency operation has a mortality rate of 20%. Peritonitis, gangrenous colon, and the use of a stoma are strong predictors of perioperative complications and mortality.

According to the literature, a stoma is used in one-half of all operations for sigmoid volvulus, either end or diverting. In contrast, Hartmann's procedure is used in 15% of elective cases and 24% of emergent cases. For our case to contribute to the current literature, we highlight some critical features. In this case, the patient's symptoms developed in 3 days, with only distended abdomen noted on physical examination. There were no signs of peritonitis upon the arrival of this patient. Upright plain film of the chest x-ray showed no sign of perforation. However, the surgical indication in this case relied on computed tomography of the abdomen and pelvis result, which suspected colonic ischemia caused by closed-loop obstruction. This patient has not had a flexible endoscopy trial for colon detorsion. A sigmoid colectomy with end colostomy (Hartmann's procedure) was the safest operation for this patient due to the twist of the mesenteric, which may cause an extension of colon ischemia postoperatively (Leong et al., 2008; Seah et al., 2005).

Recent studies showed that the mortality, anastomosis leakage, prolonged ileus, bleeding, surgical site infection, and fascial dehiscence were not different between the two groups of Hartmann's procedure and primary anastomosis significantly (Oren et al., 2007). As a final note, acquiring early computed tomography of the abdomen and pelvis is essential to assess the viability of the bowel and other abdominal complications. Symptoms may be sub-acute, and clinical signs may reveal no surgical indications in older adults. Hartmann's procedure is still a safe choice to operate on patients with gangrenous bowel in the emergent setting due to the simplicity of the technique and without the need for revision surgery.

#### 4. CONCLUSION

This case report emphasizes the importance of image studies in conditions such as bowel obstruction, especially CT scans in the setting of bowel obstruction without any abnormal clinical signs. Early cause recognition and mesenteric vascular assessment are essential for surgical planning. In this case, we noted an interesting pattern regarding symptom-to-presentation and the algorithm for diagnosing ischemic sigmoid volvulus. Furthermore, we demonstrate the emergent management in treating gangrenous sigmoid volvulus by making a Hartmann's procedure due to the simplicity of the technique.

#### Acknowledgement

We thank the participants who all contributed samples to the study.

#### Authors' Contribution

Phu V Pham had full access to all the data in the study and took responsibility for the integrity of the data and the accuracy of the data analysis.

Study concept and design: Phu V Pham, Hoa T Tran, Duy HN Nguyen.

Drafting of the manuscript: Phu V Pham, Duy HN Nguyen, Truong DA Nguyen, Phuoc T Bui.

Supervision: Lap B Duong.

#### Ethical approval

Not applicable.

#### Informed consent

Written and Oral informed consent was obtained from participant included in the study. Additional informed consent was obtained from participant for whom identifying information is included in this manuscript.

#### Funding

This study has not received any external funding.



**Conflict of interest**

The authors declare that there is no conflict of interest.

**Data and materials availability**

All data sets collected during this study are available upon reasonable request from the corresponding author.

**REFERENCES**

1. Arnold GJ, Nance FC. Volvulus of the sigmoid colon. *Ann Surg* 1973; 177(5):527-37. doi: 10.1097/00000658-197305000-00004
2. Baker DM, Wardrop PJ, Burrell H, Hardcastle JD. The management of acute sigmoid volvulus in Nottingham. *J R Coll Surg Edinb* 1994; 39(5):304-6.
3. Ballantyne GH, Brandner MD, Beart RW Jr, Ilstrup DM. Volvulus of the colon. Incidence and mortality. *Ann Surg* 1985; 202(1):83-92. doi: 10.1097/00000658-198507000-00014
4. Halabi WJ, Jafari MD, Kang CY, Nguyen VQ, Carmichael JC, Mills S, Pigazzi A, Stamos MJ. Colonic volvulus in the United States: trends, outcomes, and predictors of mortality. *Ann Surg* 2014; 259(2):293-301. doi: 10.1097/SLA.0b013e31828c88ac
5. Lal SK, Morgenstern R, Vinjirayer EP, Matin A. Sigmoid volvulus an update. *Gastrointest Endosc Clin N Am* 2006; 16(1):175-87. doi: 10.1016/j.giec.2006.01.010
6. Leong QM, Koh DC, Ho CK. Emergency Hartmann's procedure: morbidity, mortality and reversal rates among Asians. *Tech Coloproctol* 2008; 12(1):21-5. doi: 10.1007/s10151-008-0393-y
7. Madiba TE, Thomson SR, Corr P. Volvulus of the sigmoid colon. *Gastroenterol Forum* 1997; 8:28-33.
8. Mangiante EC, Croce MA, Fabian TC, Moore OF 3rd, Britt LG. Sigmoid volvulus. A four-decade experience. *Am Surg* 1989; 55(1):41-4.
9. Oren D, Atamanalp SS, Aydinli B, Yildirgan MI, Başoğlu M, Polat KY, Onbaş O. An algorithm for the management of sigmoid colon volvulus and the safety of primary resection: experience with 827 cases. *Dis Colon Rectum* 2007; 50(4):489-97. doi: 10.1007/s10350-006-0821-x
10. Raveenthiran V, Madiba TE, Atamanalp SS, De U. Volvulus of the sigmoid colon. *Colorectal Dis* 2010; 12(7 Online):e1-17. doi: 10.1111/j.1463-1318.2010.02262.x
11. Seah DW, Ibrahim S, Tay KH. Hartmann procedure: is it still relevant today? *ANZ J Surg* 2005; 75(6):436-40. doi: 10.1111/j.1445-2197.2005.03367.x