

## To Cite:

Sowmya S, Dureja S, Pranathi PS, Ganesh S, Swamy KNR, Doggalli N. A modified approach for removal of damaged implant abutments: A clinical report. *Medical Science* 2023; 27: e215ms2991.  
doi: <https://doi.org/10.54905/disssi/v27i135/e215ms2991>

## Authors' Affiliation:

<sup>1</sup>Assistant Professor, Department of Prosthodontics, JSS Dental College and Hospital, JSSAHER, Bannimantap, Mysuru, Karnataka-570015, India

<sup>2</sup>Post-Graduate Student (MDS), Department of Prosthodontics, JSS Dental College and Hospital, JSSAHER, Bannimantap, Mysuru, Karnataka-570015, India

<sup>3</sup>Clinician, Sri Sai Super Speciality Dental Hospital, Hyderabad, Telangana-500038, India

<sup>4</sup>Reader, Department of Prosthodontics, JSS Dental College and Hospital, JSSAHER, Bannimantap, Mysuru, Karnataka- 570015, India

<sup>5</sup>Professor and HOD, Department of Prosthodontics, JSS Dental College and Hospital, JSSAHER, Bannimantap, Mysuru, Karnataka- 570015, India

<sup>6</sup>Department of Oral Medicine and Radiology, JSS Dental College and Hospital, JSSAHER, Bannimantap, Mysuru, Karnataka- 570015, India

## ORCID List

Sowmya S	0000-0001-5037-4981
Shyla Dureja	0000-0002-0867-7636
Putta Sai Pranathi	0000-0002-4357-2485
Ganesh S	0000-0002-0109-5860
Raghavendra Swamy KN	0000-0001-9037-3094
Nagabhushana Doggalli	0000-0002-5890-1755

## \*Corresponding Author

Post-Graduate Student (MDS), Department of Prosthodontics, JSS Dental College and Hospital, JSSAHER, Bannimantap, Mysuru, Karnataka-570015, India

ORCID: 0000-0002-0867-7636

Email: [shyla.dureja@gmail.com](mailto:shyla.dureja@gmail.com)/[dr.ssowmya@jssuni.edu.in](mailto:dr.ssowmya@jssuni.edu.in)

## Peer-Review History

Received: 28 March 2023

Reviewed & Revised: 01/April/2023 to 24/April/2023

Accepted: 27 April 2023

Published: 02 May 2023

## Peer-review Method

External peer-review was done through double-blind method.

Medical Science

pISSN 2321-7359; eISSN 2321-7367

This open access article is distributed under [Creative Commons Attribution License 4.0 \(CC BY\)](https://creativecommons.org/licenses/by/4.0/).

# A modified approach for removal of damaged implant abutments: A clinical report

Sowmya S<sup>1</sup>, Shyla Dureja<sup>2\*</sup>, Putta Sai Pranathi<sup>3</sup>, Ganesh S<sup>4</sup>, Raghavendra Swamy KN<sup>5</sup>, Nagabhushana Doggalli<sup>6</sup>

## ABSTRACT

Dental implants have currently become an extremely popular prosthodontic treatment option for restoring function and aesthetics, owing to their effectiveness, longevity, dependability and esthetic outcome. Among the various prosthetic rehabilitation modalities for completely edentulous cases, implant-supported overdentures have a very good prognosis. Over time in use, implant-related complications like abutment damage may arise. Damaged abutments may lose their external hexagonal structure, making it challenging to engage the drivers. This makes their removal complicated and technique sensitive. The rotary devices that are used have many drawbacks that might harm the implant's internal threads during implant abutment removal. This article describes a novel method for removing a damaged mandibular overdenture abutment using an ultrasonic scaler wrench without jeopardising the implant. This conservative management was found to be simple, cost-effective and time-efficient, with no additional required equipment.

**Keywords:** Implant, Abutment, Abutment removal, Implant Complications

## 1. INTRODUCTION

Dental implants have become an increasingly popular prosthodontic treatment option for restoring function and esthetics pertaining to their ease of use, reliability, increased prosthetic retention, effectiveness and patient satisfaction. A removable overdenture prosthesis has been a more comfortable, retentive and satisfying rehabilitative alternative to a conventional complete denture. Multiple overdenture attachments are accessible in the market, including splinted (clip and bar attachments) and non-splinted attachments (locator, magnetic and ball attachments) (Mirchandani et al., 2021).

The most common type of attachment used in the overdenture has been the ball attachment. In this procedure, a sphere-shaped metal alloy or plastic abutment is inserted into an attachment metal housing, which is then incorporated into the dentures. It has multiple advantages such as a simple production process, a wide range of movement, increased retention, better hygiene maintenance, affordability and increased patient satisfaction.

Furthermore, the O-ring requires replacement regularly due to wear (Mirchandani et al., 2021). It provides a more affordable option than a fixed implant-supported complete denture. The mandibular overdentures supported by 2 and 4 implants have a high survival rate according to the literature studies (Taira and Sawase, 2012; Thiesen et al., 2014).

However, many implant-related complications have been reported. These include implant malposition, implant failures, abutment damage and abutment screw fracture. The aetiology of these technical failures includes excessive occlusal pressure, fatigue, improper placement procedures and an active fit of the superstructures, design and manufacturing failures and the use of unfavourable components such as duplicate products (Luterbacher et al., 2000; Nergiz et al., 2004; Shah and Lee, 2016).

Implant-supported overdentures necessitate the replacement of their abutment connections and prosthesis regularly. Because of the previously mentioned factors, the abutments can also wear out over time and require replacement. Abutments that have been damaged may lose their external hexagonal structure, creating difficulty to engage the drivers. This makes its removal difficult and technique sensitive. Multiple risks are associated with using the rotary device, which could damage the implant's internal threads during implant abutment removal (Shedmake et al., 2022). This article explains a simple yet efficient technique for removing a damaged overdenture abutment without compromising the implant.

## 2. CASE REPORT

A 75-year-old male patient presented to the Prosthodontics department with an Implant retained overdenture prosthesis. The patient gave a history of implant placement (HiTech Implants, Israel) 15 years ago, along with ball retained overdenture fabrication. The patient gave a history of replacement of the dentures along with the O-ring attachment every 5 years. The patient also reported numerous failed attempts to retrieve the overdenture ball abutments, possibly causing minor damage to the abutment. Clinically, the implants were stable and firm without any mucosal inflammation. Radiographs revealed slight crestal bone loss.

The overdenture ball abutments had severely worn out and had irregularities on its surface. The patient desired a new prosthesis on the same implants; thus, it was decided to replace the previous abutments with new ones (Figure 1). As the abutments structure was damaged, the removal of the same was quite challenging. Multiple techniques were tried to remove it without damaging the implants. This article presents a modified approach for the removal of a damaged mandibular overdenture abutment without compromising the implant.

### Removal using the driver of the same system

Since the external hexagonal structure of the attached abutment was damaged, the driver (HiTech) did not precisely engage for the abutment removal (Taira and Sawase, 2012; Thiesen et al., 2014).

### Removal using the driver of another system

Adin (Israel) implant driver was for the abutment removal. The driver was not accurately adapting to the external hexagonal structure of the attached abutment. Thus, to increase the grip, Teflon tape was placed on the abutment followed by the placement of the driver. Even though the grip increased, it did not engage the abutments.

### Removal using a needle holder

A curved needle holder was used to hold the external surface of the abutment to aid in its removal.

### Removal using a modified technique

An ultrasonic scaler wrench was used to engage the abutments and aid in removal (Figure 2).

An airtor was used to create 2 parallel walls on the external abutment surface.

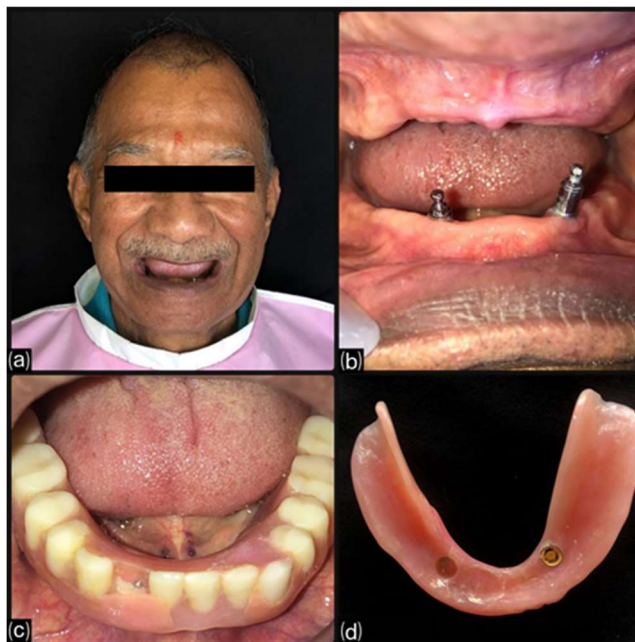This was used to engage the ultrasonic scaler wrench, along the prepared parallel walls of the abutment.

Slight finger pressure was applied, to move the whole assembly. After a couple of turns, the abutment was successfully removed.

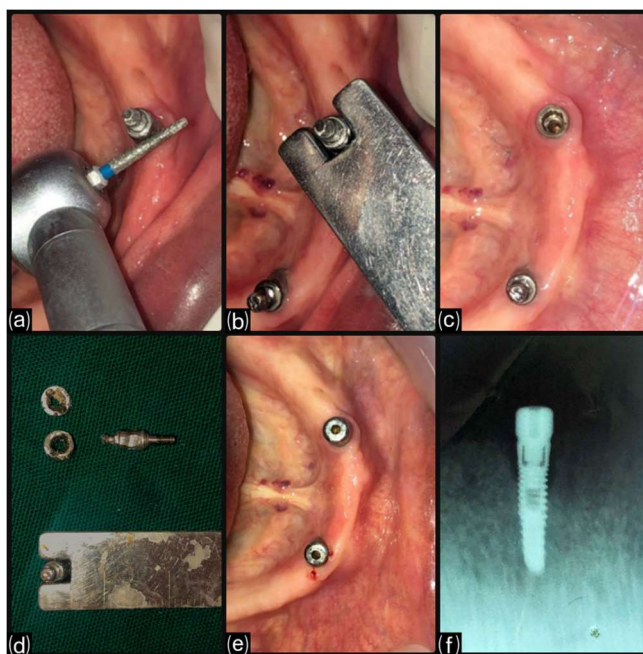
The implant's internal hex was observed and it appeared to be in good condition to accept new abutments.

The healing abutments (HiTech) were used to replace the previously placed abutments.

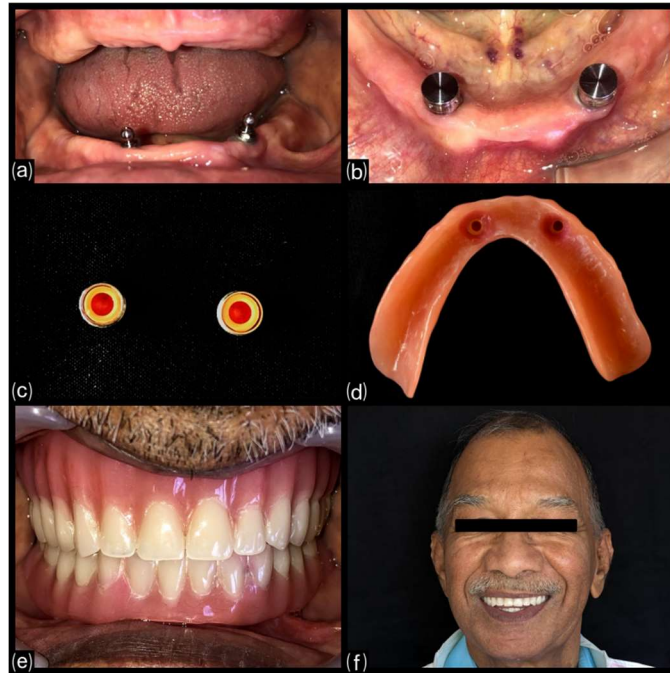New ball abutments (Adin) were placed on the implants which were followed by the fabrication of new implant-supported overdenture prosthesis (Figure 3).



**Figure 1** (a) Extra Oral Image, (b) Intra Oral Image, (c) Prefabricated Dentures (Occlusal View), (d) Prefabricated Dentures (Intaglio View)



**Figure 2** (a) Creation of parallel walls using arotor, (b) Engaging the driver, (c) Abutment removal, (d) Removed abutments with metal housing, (e) Healing abutments placed, (f) IOPAR with healing abutment



**Figure 3** (a) Intra Oral Image with new ball abutments, (b) Intra Oral Image with metal housing, (c) Metal Housing with O-Rings, (d) Fabricated Mandibular Denture (Intaglio View) (e) Fabricated Dentures (f) Post Treatment Extra Oral Image

### 3. DISCUSSION

Many patients report satisfaction with their previously used implant-supported overdentures (Thiesen et al., 2014). The prosthetic components of the dentures as well as the abutments deteriorate over time. Therefore, their replacement is necessary to maintain the prostheses and implants' effective functionality. According to Fromentin et al., (2011) compared to unused components, the mean ball abutments diameter decreased by 22 to 31  $\mu\text{m}$  following 8 years of clinical usage. After an average of 3.3 years of clinical usage, the abutments reached their maximum degree of wear. This could be attributed to the fact that the posterior portions of the prosthesis rotated around the ball attachments when they were loaded during function thus protecting the implants from excessive bending moments. These movements, which were primarily backwards-forward, might have caused the patrix to distort and wear out, especially on the mating surfaces (Fromentin et al., 2011).

As the implant abutments wear out, there is a risk of fracture to the prosthesis or the implants. The patient's quality of life and masticatory performance may be compromised by the loss of denture retention caused by the progressive wear of an implant-supported overdenture's component parts. Therefore, replacing the abutments and the prosthetic components on a regular basis is beneficial. Literature suggests the replacement of the abutments every 2-4 years (Choi et al., 2017; Fromentin et al., 2011). Over the years, there have been numerous implant systems in the market (Luterbacher et al., 2000). Each implant system necessitates its custom-made toolkit and driver for component placement and removal. However, clinicians are only closely associated with a subset of the implant systems (Kurt et al., 2013).

Replacement of prosthetic connections becomes a challenging task for the clinician when they find themselves in a position where they do not have the kit to deal with a particular system or where the abutments structure is damaged to accept the removal using its appropriate system driver. Even though retrieving a compromised abutment and restoring it with a brand new one without inflicting damage to the implant's internal threads is the preferred solution, in some cases, the damaged abutments cannot be replaced by their system drivers. In such, conditions, external means of removal must be thought about. It is important to maintain the integrity of the priorly placed implant.

This article presents a modified approach for removing a damaged mandibular overdenture abutment without compromising the implant. Simply by modifying the external walls of the abutment with an airtor, the damaged abutment could be easily removed using an ultrasonic scaler wrench. This technique could be used with most implant systems, with different abutment designs and abutments with damaged external surfaces.



## 4. CONCLUSION

Numerous efforts performed previously to retrieve damaged abutments had failed, possibly causing minor damage to the abutment's hexagonal surface. This article offers a modified approach for detaching a damaged mandibular overdenture abutment using an ultrasonic scaler wrench without compromising the implant. This conservative management was found to be simple, non-surgical, cost-effective and time-efficient, requiring no additional equipment.

## Acknowledgements

The study was supported by the Department of Prosthodontics and Crown and Bridge at the JSS Dental College and Hospital, JSS Academy of Higher Education & Research, Mysuru, Karnataka, India.

## Author's contribution

All the authors contributed equally to the case report

## Informed consent

Written informed consent was obtained from the patient who participated in the study

## Funding

This study has not received any external funding.

## Conflict of interest

The authors declare that there is no conflict of interests.

## Data and materials availability

All data sets collected during this study are available upon reasonable request from the corresponding author.

## REFERENCES AND NOTES

- Choi JW, Bae JH, Jeong CM, Huh JB. Retention and wear behaviors of two implant overdenture stud-type attachments at different implant angulations. *J Prosthet Dent* 2017; 117(5):628–635. doi: 10.1016/j.prosdent.2016.09.027
- Fromentin O, Lassauzay C, Nader SA, Feine J, Albuquerque RF. Clinical wear of over denture ball attachments after 1, 3 and 8 years. *Clin Oral Implants Res* 2011; 22(11):1270–1274. doi: 10.1111/J.1600-0501.2010.02102.X
- Kurt M, Güler AU, Duran I. A Technique for Removal of a Fractured Implant Abutment Screw. *J Oral Implantol* 2013; 39(6):723–725. doi: 10.1563/AAID-JOI-D-11-00017
- Luterbacher S, Fourmouis I, Lang NP, Brägger U. Fractured prosthetic abutments in osseointegrated implants: A technical complication to cope with. *Clin Oral Implants Res* 2000; 11(2):163–170. doi: 10.1034/J.1600-0501.2000.110209.X
- Mirchandani B, Zhou T, Heboyan A, Yodmongkol S, Buranawat B. Biomechanical Aspects of Various Attachments for Implant Overdentures: A Review. *Polymers (Basel)* 2021; 13(19). doi: 10.3390/POLYM13193248
- Nergiz I, Schmage P, Shahin R. Removal of a fractured implant abutment screw: A clinical report. *J Prosthet Dent* 2004; 91(6):513–517. doi: 10.1016/J.PROSDENT.2004.03.010
- Shah K, Lee DJ. An alternative approach for the management of fractured implant abutment screws on a mandibular implant-retained over denture: A clinical report. *J Prosthet Dent* 2016; 115(4):402–405. doi: 10.1016/J.PROSDENT.2015.09.027
- Shedmake S, Awate N, Walke P. The dental abutment screw and new methods to remove fractured abutment screw from jawbone: A review. *Mater Today Proc* 2022; 60:2254–2256. doi: 10.1016/J.MATPR.2022.03.398
- Taira Y, Sawase T. A Modified Technique for Removing a Failed Abutment Screw from an Implant with a Custom Guide Tube. *J Oral Implantol* 2012; 38(2):165–169. doi: 10.1563/AAID-JOI-D-10-00162
- Thiesen CH, Filho RR, Maykot-Prates LH, Sartori N. Success and survival rates of mandibular overdentures supported by two or four implants: A systematic review. *Braz Oral Res* 2014; 28(6):74–80. doi: 10.1590/S1806-83242013000600012