

MEDICAL SCIENCE

To Cite:

Nawkhare AV, Shamal S, Udhoji SP, Seth N. Convalescence after physiotherapy intervention in a classic rare case of cerebellar bleed: A case report. *Medical Science* 2023; 27: e197ms2950.
doi: <https://doi.org/10.54905/disssi/v27i134/e197ms2950>

Authors' Affiliation:

¹Intern, Department of Neuro physiotherapy, Ravi Nair Physiotherapy College, Datta Meghe Institute of Higher Education and Research (Deemed to be university), Sawangi (Meghe), Wardha, Maharashtra, India.

²Assistant Professor, Department of Neuro physiotherapy, Ravi Nair Physiotherapy College, Datta Meghe Institute of Higher Education and Research (Deemed to be university), Sawangi (Meghe), Wardha, Maharashtra, India.

³Resident, Department of Neuro physiotherapy, Ravi Nair Physiotherapy College, Datta Meghe Institute of Higher Education and Research (Deemed to be university), Sawangi (Meghe), Wardha, Maharashtra, India.

Contact List

Anjali Vikas Nawkhare	anjalinawkhare@gmail.com
Snehal Shamal	snehalsamal11@rediffmail.com
Swadha P Udhoji	swadhamushriff@gmail.com
Nikita Seth	nikitasheth1999@gmail.com

ORCID List

Anjali Vikas Nawkhare	0000-0003-0747-1625
Snehal Shamal	0000-0003-0105-2411
Swadha P Udhoji	0000-0002-9945-9959
Nikita Seth	0000-0003-4103-9895

*Corresponding Author

Assistant Professor, Department of Neuro Physiotherapy, Ravi Nair Physiotherapy College, Datta Meghe Institute of Medical Sciences (Deemed to be university), Sawangi (Meghe), Wardha, Maharashtra, India
Email: snehalsamal11@rediffmail.com
ORCID: 0000-0003-0105-2411

Peer-Review History

Received: 02 March 2023
Reviewed & Revised: 06/March/2023 to 16/April/2023
Accepted: 18 April 2023
Published: 24 April 2023

Peer-review Method

External peer-review was done through double-blind method.

Medical Science
pISSN 2321-7359; eISSN 2321-7367

This open access article is distributed under [Creative Commons Attribution License 4.0 \(CC BY\)](https://creativecommons.org/licenses/by/4.0/).

Convalescence after physiotherapy intervention in a classic rare case of cerebellar bleed: A case report

Anjali Vikas Nawkhare¹, Snehal Shamal^{2*}, Swadha P Udhoji³, Nikita Seth³

ABSTRACT

The cerebellum regulates posture, eye-hand coordination and limb movement. It may also have a role in non-motor functions including attention and cognition. The feedforward component of movement is impacted by inadequate predictive control, which is linked to the motor symptoms of cerebellar impairment. Cerebellar haemorrhage or hematoma is a type of intracranial haemorrhage (ICH). In the cerebellum or posterior fossa, bleeding accounts for 9% to 10% of all ICH cases. Nontraumatic cerebral haemorrhage can cause 9% to 27% of strokes globally, with an annual incidence of 12 to 31 per 100,000 people. The prevalence varies by race and age. In this case, we reported a 74-year-old male with a known history of hypertension came with a complaint of sudden onset 3 to 4 episodes of vomiting, dizziness, headache, slurred speech and weakness in all four limbs. On investigation, the patient was diagnosed with cerebellar haemorrhage. Managed operatively that is an evacuation of the brainstem haematoma. The patient was referred to the neuro physiotherapy department for further management. The Physiotherapy protocol was 6 weeks with increased muscle strength, range of motion (ROM) and normalized tone, to achieve normal reflexes and to develop balance & postural stability.

Keywords: Cerebellar haemorrhage, Cerebellar lesion, Rehabilitation, Neuro physiotherapy, Rood's approach.

1. INTRODUCTION

An incidence of cerebellar haemorrhage is one in which the posterior fossa or cerebellum is the site of the bleeding. The most common age groups for this disease are middle-aged and older adults (Fischer and Das, 2022). Cerebellar hematomas can block the cerebral spinal fluid from draining normally, which can cause hydrocephalus, higher intracranial pressure and the start of symptoms (Fischer and Das, 2022). Cerebellar haemorrhage or hematoma is a type of intracranial haemorrhage (ICH). Approximately 9% to 10% of all ICH are caused by bleeding that occurs in the cerebellum or posterior fossa (Datar

and Rabinstein, 2014). Prevalence depending on race and age, nontraumatic cerebral haemorrhage can cause 9% to 27% of strokes worldwide, with an annual incidence of 12 to 31 per 100,000 people (Feigin et al., 2009). The rate is most prevalent in Asian populations, lowest in White populations and middle for Black populations (Flaherty et al., 2005).

Initial signs of cerebellar infarction or haemorrhage can include headache, dizziness, nausea, vomiting and vertigo. More than 50% of cerebellar strokes are accompanied by nausea and vomiting and around 75% of them are accompanied by dizziness. Additionally, patients frequently have a diminished state of consciousness; 26% of them exhibit lethargy and 3% present with coma (Wright et al., 2014). 90% of patients with cerebellar infarction exhibit localising symptoms such as truncal and appendicular ataxia, nystagmus and difficulty speaking (Lee et al., 2006). The cerebellum controls eye stability reduction, correction and ocular alignment maintenance. Ocular instability, saccadic intrusions, impaired VOR, nystagmus, impaired smooth pursuit and ocular misalignment are among the abnormalities brought on by cerebellar lesions. Recent developments made it possible to find trustworthy structural-clinical relationships (Bodranghien et al., 2016). The disability brought on by a stroke can affect a person's ability to carry out their daily activities as well as how their body functions. Restoring and maybe increasing independence with ADLs is the main goal of stroke treatment (Jaiswal et al., 2022).

The general consensus is that people with chronic hypertension develop microaneurysms, which burst and cause bleeding, as a result of degenerative changes in the walls of very small blood vessels (Garcia and Ho, 1992). The cerebellar syndrome is the outcome of a diverse spectrum of illnesses and can manifest as systemic symptoms, in isolation or in conjunction with a variety of neurological manifestations. When given instructions to conduct smooth movements and goal-directed tasks, the patient will frequently be subjected to a cerebellar evaluation. As shown here, there are a number of causes for these flaws (Mitoma et al., 2020).

A number of evidence-based therapy strategies are used by physiotherapists to enhance overall function. Progressive resistance training, virtual reality, aerobic exercise, mirror therapy and training focused on walking, balance and upper limb & lower limb function are a few examples of interventions (Ontario Health (Quality), 2020). In this case, the patient had 3 to 4 episodes of vomiting, dizziness, headache, slurred speech and weakness in all four limbs and on investigation patient confirmed the diagnosis with cerebellar haemorrhage. Then the patient was operated on for the evacuation of brainstem haematoma. The patient was referred to neuro-physiotherapy after 8 weeks patient achieved.

2. CASE PRESENTATION

A 74-year-old male was apparently alright before 11/11/22 then he had 3to4 episodes of vomiting, dizziness, headache, slurred speech and weakness in all four limbs. Then the patient was brought by his relative to super speciality hospital with a history of 3 to 4 episodes of vomiting, dizziness, headache, slurred speech and weakness in all four limbs. The patient was on hypertensive medication thus was a known case of hypertension since 2 years. Then immediate further investigation was done i.e., MRI & CT-scan. On investigation, the patient was diagnosed with cerebellar haemorrhage. Managed operatively that is an evacuation of the brainstem haematoma. The patient was referred to the neuro physiotherapy department for further management.

3. CLINICAL FINDING

On examination, the patient was conscious and cooperative. The patient was supine lying position with the head elevated 30°. All sensations are intact. The tone is hypotonia in the pre-rehabilitation assessment is shown (Table 1). The muscle strength of the patient evaluates by assessing muscle manual testing as shown (Table 2). Patient cortical & superficial reflexes are intact bilaterally. Deep Reflexes are absent in pre-rehabilitation & post-rehabilitation patients achieve normal reflexes. In voluntary control grading pre-rehabilitation is 0 shown (Table 3). Using some outcome measures pre-rehabilitation and post-rehabilitation that are shown (Table 4). An investigation was done with an MRI & CT scan of the brain shown (Figure 1, 2, 3).

Investigations

MRI

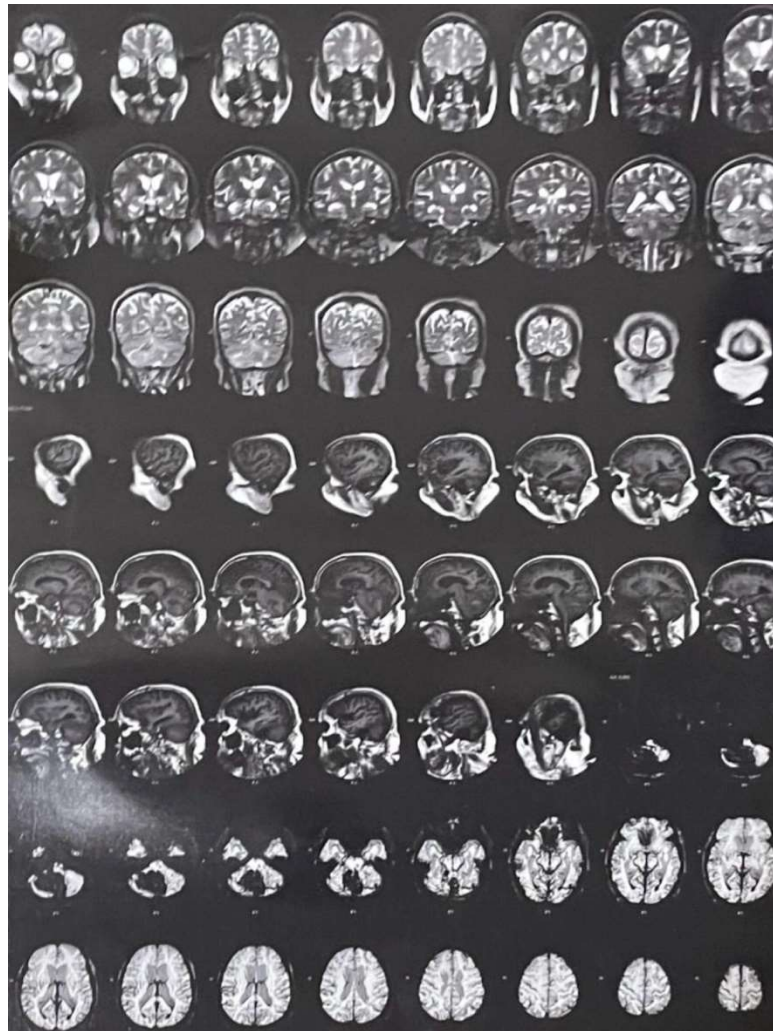


Figure 1 MRI shows the prominent bilateral ventricles and basal cisterns are noted. Age-related cerebral atrophic changes. Confluent FLAIR hyper intensities are noted in bilateral periventricular white matter-Periventricular ischemia. FLAIR hyper intense foci are noted in bilateral centrum semiovale and corona radiata-Ischemic foci

CT-SCAN of brain

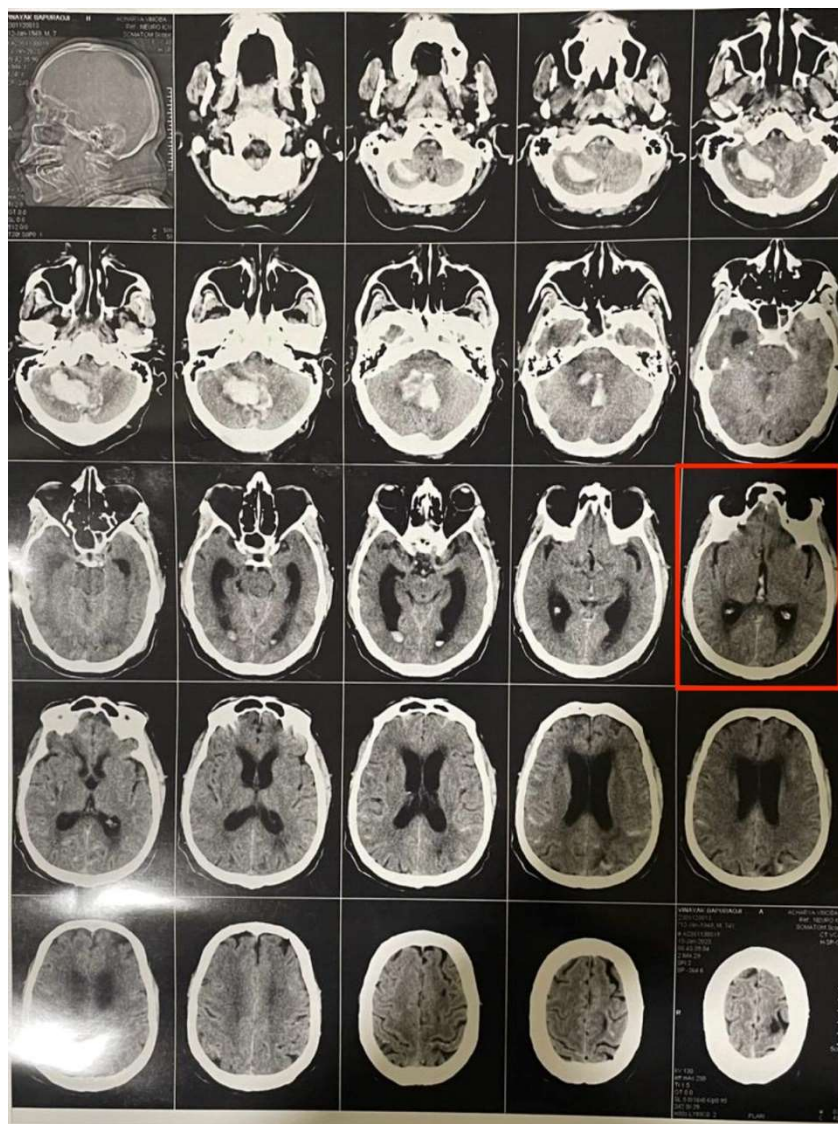

Figure 2 Preoperative CT-Scan of the brain shows the intraparenchymal haemorrhage in bilateral cerebellar hemispheres with intraventricular extension as described above

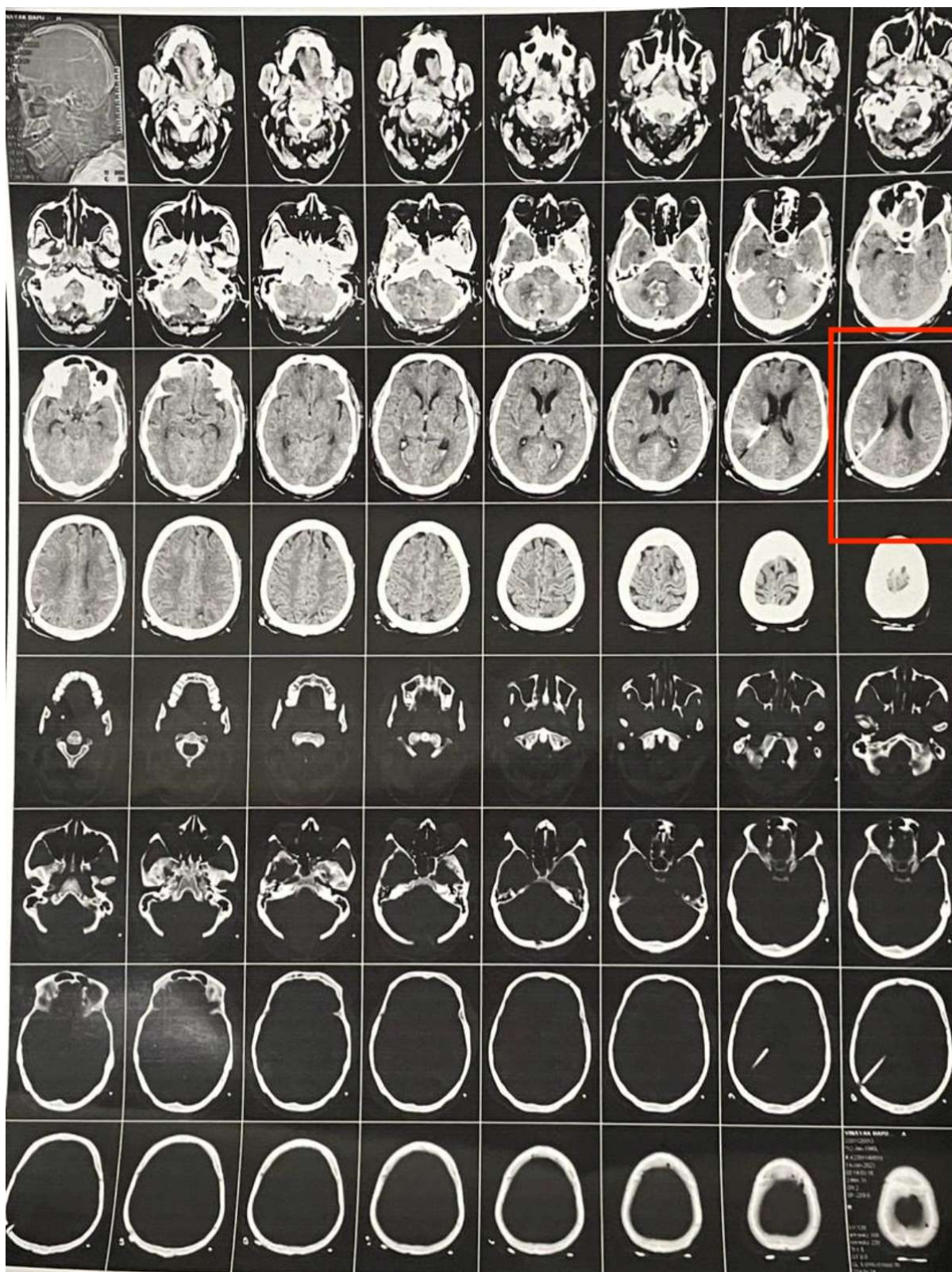


Figure 3 Postoperative CT-Scan of the brain showed the post-operative changes noted in the form of calvarial defect in the right parietal and occipital bone with overlying extra calvarial soft tissue swelling, blood and air density foci, surgical clips and burr hole defect in right parietal bone with up shunt placement

Tone assessment**Table 1** Tone assessment

	Pre-rehabilitation left	Post rehabilitation left
Shoulder flexors	1+(Hypotonia)	2+Normal
Shoulder extensors	1+(Hypotonia)	2+Normal
Shoulder abductors	1+(Hypotonia)	2+Normal
Shoulder adductors	1+(Hypotonia)	2+Normal
Elbow flexors	1+(Hypotonia)	2+Normal
Elbow extensors	1+(Hypotonia)	2+Normal
Wrist flexors	Normal	2+Normal
Wrist extensors	Normal	2+Normal
Hip flexors	1+(Hypotonia)	2+Normal
Hip extensors	1+(Hypotonia)	2+Normal
Knee flexors	1+(Hypotonia)	2+Normal
Knee extensors	1+(Hypotonia)	2+Normal
Ankle dorsiflexors	Normal	2+Normal
Ankle plantarflexors	Normal	2+Normal

Reflexes**Table 2** Reflexes

	Pre-rehabilitation left	Post rehabilitation left
Biceps jerk	Absent	Normal
Triceps jerk	Absent	Normal
Supinator jerk	Absent	Normal
Knee jerk	Absent	Normal
Ankle jerk	Absent	Normal
Plantar response	Absent	Normal

Voluntary control grading (VCG)**Table 3** Voluntary control grading (VCG)

	Pre-rehabilitation left Side	Post rehabilitation Left side
Shoulder flexors	0	5
Shoulder extensors	0	5
Shoulder abductors	0	5
Shoulder adductors	0	5
Elbow flexors	0	5
Elbow extensors	0	6
Wrist flexors	0	6
Wrist extensors	0	6
Hip flexors	0	6
Hip extensors	0	5
Knee flexors	0	5
Knee extensors	0	5
Ankle dorsiflexors	0	6
Ankle plantarflexors	0	6

Physiotherapy Intervention

The patient was treated using a multidisciplinary approach that included a group of doctors, nurses, physiotherapists, speech therapists and occupational therapists in order to achieve a positive outcome. The major objectives of physical therapy treatments

were to improve the patient's quality of life and prevent further difficulties. These treatments were planned with functional goals. Also, patient assesses with using outcome measures is shown (Table 4).

Problem list

1. Hypotonia
2. Decrease muscle strength & ROM
3. Balance issue
4. Nystagmus
5. Ataxic gait

Short-term goals

Patient education, transition, to increase muscle strength, range of motion (ROM), normalized tone, to achieve normal reflexes and to develop balance & postural stability

Long-term goals

To maintain muscle strength, range of motion (ROM), to maintain postural stability and balance & Gait training.

Week 01 to week 02

1. Educated patient and family about their condition and how physiotherapy helps in this condition.
2. Positioning & transition i.e., log rolling, supine lying to sit. A transition showed (Figure 6).
3. Active mobility exercises for the right upper limb & lower limb: Active range of motion exercise helps in preserving joint and soft tissue flexibility & reduces the chances of developing contracture.
4. Rood's facilitation approach for the left upper limb & lower limb. Facilitatory techniques help to improve the tone of flaccid muscles. In facilitatory techniques, tactile stimulation is light touch using a cotton swab. Tapping helps to facilitate the muscle by being applied over the tendon or muscle bulk.
5. Passive movement for left upper limb & lower limb. Passive movement of the wrist & elbow is shown (Figure 4, 5).
6. Unilateral bridging.

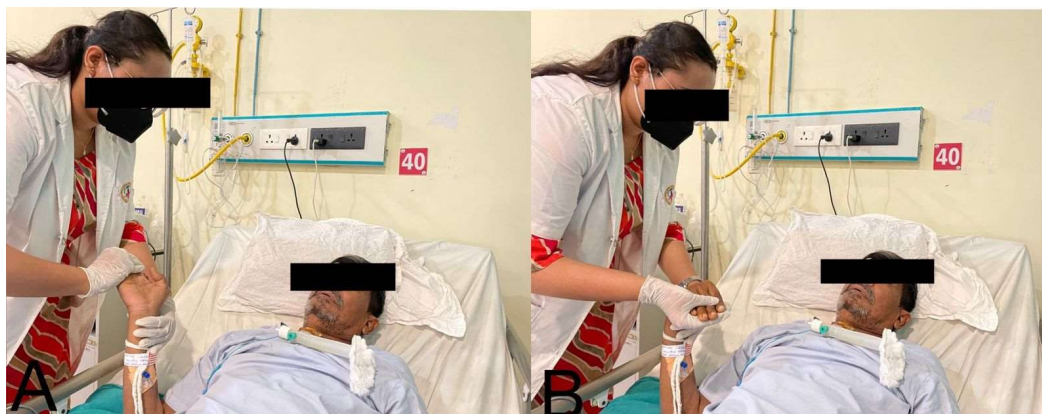

Figure 4 Passive range of motion exercise for wrist. A) Wrist extension; B) Wrist flexion

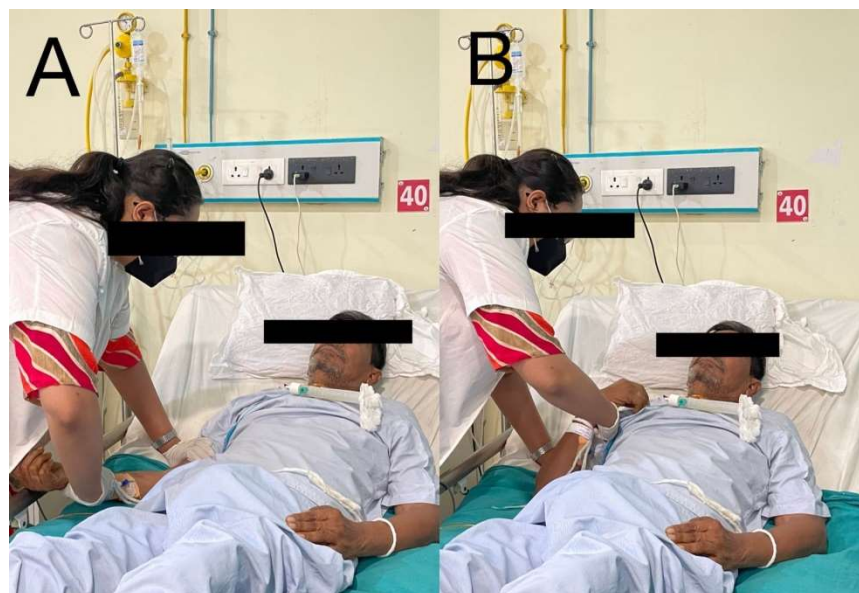


Figure 5 Passive range of motion exercise for elbow. A) Elbow extension B) Elbow flexion

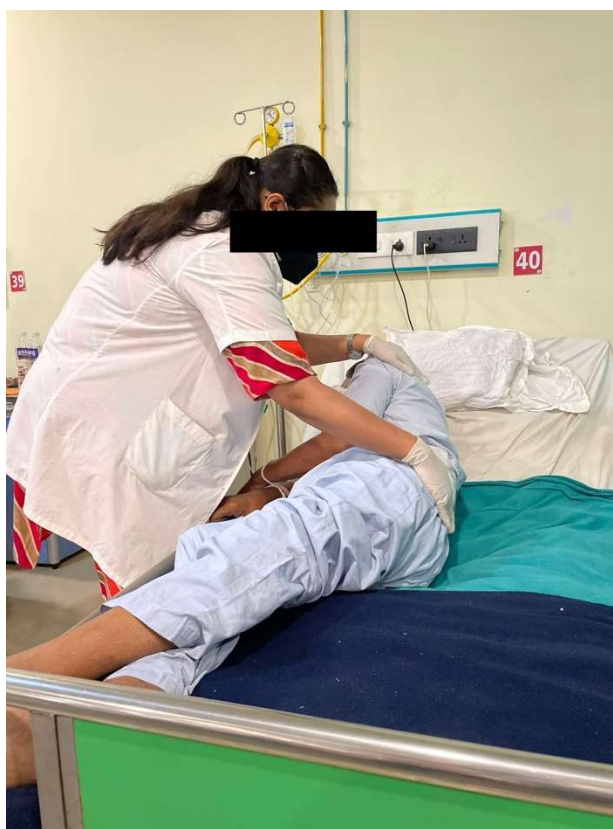

Figure 6 Transition log rolling

Week 03 to week 04

1. Sitting balance: Static & dynamic balance sitting activities for achieving the sitting balance.

For static balance: The patient sits on a stable surface unsupported for 1-2min after that therapist gives gentle pushes in all directions.

Dynamic balance: Patient achieves static balance for dynamic balance reach out activities for achieving dynamic balance in sitting. The patient performs various tasks in this position that is grooming & holding a medicine ball.

2. Non-equilibrium exercise-fingers to therapist's finger, finger to finger & alternate nose to finger

3. Sitting to standing–the patient is sitting on the bed the feet are in proper contact with the ground. Now therapist stabilized the knee and support the pelvis after that patient is encouraged to stand.
4. Equilibrium exercise–standing feet together & heel to the shin (Figure 7).
5. Gaze and eye movement exercises.

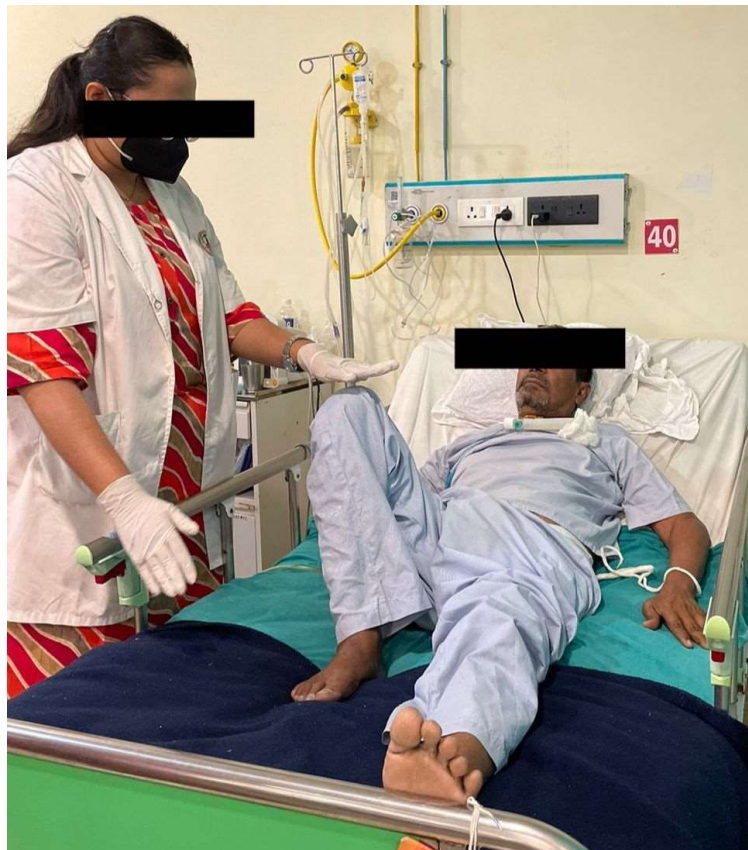

Figure 7 Patient performing equilibrium exercise heel to shin

Week 05 to week06

Goals: Gait training & maintain coordination.

1. Gait training–Initially started with using a parallel bar with footmarks. Footmarks help to reduce the tendency of a wide base of support. Progressed to outside walk with an assistive device
2. Frenkel's exercises–Effective for improving coordination. Frenkel's exercise in lying, sitting & standing

Week 07 to week08

Goals: Gait training & Improve endurance.

1. Progression in gait training–Walking on a treadmill & walking with obstacles.
2. Resistance training–Submaximal resistance exercise to improve muscle fatigue resistance.
3. Aerobic exercise–Walking and stationary cycling to improve overall endurance.

Outcome measure

Table 4 Outcome measures

	Pre-rehabilitation left Side	Post rehabilitation Left side
Voluntary control grading	Grade 0	Grade 6
Motor Assessment Scale	1	4
FIM	30	126

4. DISCUSSION

The cerebellum, which processes both motor orders and sensory feedback, plays a crucial part in regulating the timing of muscle activation (Marsden and Harris, 2011). The cerebellum is crucial in regulating saccadic eye movements and maintaining a fixed gaze. Many oculomotor behaviours and related psychophysiological systems are impaired by cerebellar injuries. Those limitations significantly affect how well rehabilitation strategies work for people with cerebellar tumours (Shurupova et al., 2021). Using strength training for the side that is less involved and a motor relearning programme and proprioceptive neuromuscular facilitation for the side that is more involved, the task-oriented approach is applied with bilateral training patients (Harjpal et al., 2021). In this instance, early physiotherapy interventions were made to speed the patient's recovery and enable him to resume his regular activities and occupation (Harjpal et al., 2022).

Marsden and Harris, (2011) conducted a systemic review & concluded that physiotherapy has positive effects on a variety of outcomes, especially balance, gait and function. The usefulness of physiotherapy in treating adults with cerebellar impairment has supported this evidence (Martin et al., 2009).

The Rood approach's fundamental tenet is the normalisation of tone through sensory stimulation. The normalisation of muscular tone is aided by the ability of sensory stimuli to both stimulate and inhibit muscle action (Bordoloi and Deka, 2018). According to Linkous and Stutts, (1990) in patients with hypotonic disorders, tactile stimulation can improve muscle tone. In patients with a degenerative cerebellar condition, a home-based balance exercise programme may help with locomotion and balance (Keller and Bastian, 2014). Pavlikova et al., (2020) conducted a multi-centre prospective study suggesting that static balance improvement was helped by physiotherapy. The degree of disability and the therapy's intensity are the main variables influencing how well it works to improve the balance (Pavlikova et al., 2020).

5. CONCLUSION

Cerebellar region's main function is tone equilibrium and balance; in this case, we achieve the fastest recovery. The patient achieves sitting & standing balance, normalized tone, as well as patient, increased muscle strength & range of motion on the left side. Functionally patient independently walks using a cane & increasing his quality of life.

Acknowledgement

We thank the participants who all contributed samples to the study.

Author contribution

Details of the contribution of each author regard manuscript work and production.

Anjali Vikas Nawkhare – Principal investigator

Dr Snehal Samal, Dr Swadha P Udhoji, Dr Nikita Seth – Supervisor

Informed consent

Written and Oral informed consent was obtained from all individual participants included in the study. Additional informed consent was obtained from all individual participants for whom identifying information is included in this manuscript.

Funding: This study has not received any external funding.

Conflict of interest

The authors declare that there is no conflict of interests.

Data and materials availability

All data sets collected during this study are available upon reasonable request from the corresponding author.

REFERENCES AND NOTES

1. Bodranghien F, Bastian A, Casali C, Hallett M, Louis ED, Manto M, Mariën P, Nowak DA, Schmahmann JD, Serrao M, Steiner KM, Strupp M, Tilikete C, Timmann D, Dun KV. Consensus Paper: Revisiting the Symptoms and Signs of Cerebellar Syndrome. *Cerebellum* 2016; 15(3):369–391.

2. Bordoloi K, Deka RS. Scientific Reconciliation of the Concepts and Principles of Rood Approach. *Int J Health Sci Res* 2018; 8(9).
3. Datar S, Rabinstein AA. Cerebellar hemorrhage. *Neurol Clin* 2014; 32(4):993–1007.
4. Feigin VL, Lawes CMM, Bennett DA, Barker-Collo SL, Parag V. Worldwide stroke incidence and early case fatality reported in 56 population-based studies: A systematic review. *Lancet Neurol* 2009; 8(4):355–369.
5. Fischer MA, Das JM. Cerebellar Hematoma. In: Stat Pearls (Internet) 2022. <https://www.ncbi.nlm.nih.gov/books/NBK541076/>
6. Flaherty ML, Woo D, Haverbusch M, Sekar P, Khoury J, Sauerbeck L, Moomaw CJ, Schneider A, Kissela B, Kleindorfer D, Broderick JP. Racial variations in location and risk of intracerebral hemorrhage. *Stroke* 2005; 36(5):934–937.
7. Garcia JH, Ho KL. Pathology of hypertensive arteriopathy. *Neurosurg Clin N Am* 1992; 3(3):497–507.
8. Harjpal P, Qureshi MI, Kovela RK, Jain M. Efficacy of Bilateral Lower Limb Training over Unilateral to Re-educate Balance and Walking in Post-stroke Survivors: A Protocol for Randomized Clinical Trial. *J Pharm Res Int* 2021; 33:281–287.
9. Harjpal PL, Kovela RK, Qureshi MI, Salphale VG. Novelty in Exercise Regimen towards Bilateral Training in a Patient after a Cerebrovascular Event. *J Clin Diagn Res* 2022; 16(11): YD01-YD03.
10. Jaiswal PR, Dadgal R, Qureshi MI, Harjpal P. Rehabilitating a patient with ischemic stroke & epileptic disorder: A case report. *Med Sci* 2022; 26(123):1.
11. Keller JL, Bastian AJ. A Home Balance Exercise Program Improves Walking in People with Cerebellar Ataxia. *Neurorehabil Neural Repair* 2014; 28(8):770–778.
12. Lee H, Sohn SI, Cho YW, Lee SR, Ahn BH, Park BR, Baloh RW. Cerebellar infarction presenting isolated vertigo: Frequency and vascular topographical patterns. *Neurology* 2006; 67(7):1178–1183.
13. Linkous LW, Stutts RM. Passive tactile stimulation effects on the muscle tone of hypotonic, developmentally delayed young children. *Percept Mot Skills* 1990; 71(3 Pt 1):951–954.
14. Marsden J, Harris C. Cerebellar ataxia: Pathophysiology and rehabilitation. *Clin Rehabil* 2011; 25(3):195–216.
15. Martin C, Tan D, Bragge P, Bialocerkowski A. Effectiveness of physiotherapy for adults with cerebellar dysfunction: A systematic review. *Clin Rehabil* 2009; 23(1):15–26.
16. Mitoma H, Buffo A, Gelfo F, Guell X, Fucà E, Kakei S, Lee J, Manto M, Petrosini L, Shaikh AG, Schmähmann JD. Consensus Paper. Cerebellar Reserve: From Cerebellar Physiology to Cerebellar Disorders. *Cerebellum* 2020; 19(1): 131–153.
17. Ontario Health (Quality). Continual Long-Term Physiotherapy After Stroke. *Ont Health Technol Assess Ser* 2020; 20(7):1–70.
18. Pavlikova M, Cattaneo D, Jonsdottir J, Gervasoni E, Stetkarova I, Angelova G, Markova M, Prochazkova M, Prokopiushova T, Hruskova N, Reznickova J, Zimova D, Spanhelova S, Rasova K. The impact of balance specific physiotherapy, intensity of therapy and disability on static and dynamic balance in people with multiple sclerosis: A multi-center prospective study. *Mult Scler Relat Disord* 2020; 40:101974.
19. Shurupova MA, Kasatkin VN, Anisimov VN, Latanov AV. Effects of Cerebellar Dysfunction Acquired as a Result of Tumor Therapy on the Functioning of the Saccadic System in Children. *Neurosci Behav Physiol* 2021; 51(3):402–409.
20. Wright J, Huang C, Strbian D, Sundararajan S. Diagnosis and Management of Acute Cerebellar Infarction. *Stroke* 2014; 45(4):e56–e58.