

Ludwig's angina after severe thrombocytopenia associated with dengue fever in a primigravida: A case report

To Cite:

Dronamraju S, Acharya S, Jain S, Bagga C, Sunil Kumar. Ludwig's angina after severe thrombocytopenia associated with dengue fever in a primigravida: A case report. Medical Science, 2022, 26, ms7e1921. doi: <https://doi.org/10.54905/disssi/v26i119/ms7e1921>

Author Affiliation:

^{1,4}Post graduate resident, Department of Medicine, Jawaharlal Nehru Medical College, Datta Meghe Institute of Medical Sciences (Deemed to be University), Sawangi (Meghe), Wardha, Maharashtra, India

²Professor and Head, Department of Medicine, Jawaharlal Nehru Medical College, Datta Meghe Institute of Medical Sciences (Deemed to be University), Sawangi (Meghe), Wardha, Maharashtra, India

³Professor, Department of ENT, Jawaharlal Nehru Medical College, Datta Meghe Institute of Medical Sciences (Deemed to be University), Sawangi (Meghe), Wardha, Maharashtra, India

⁵Professor, Department of Medicine, Jawaharlal Nehru Medical College, Datta Meghe Institute of Medical Sciences (Deemed to be University), Sawangi (Meghe), Wardha, Maharashtra, India

Peer-Review History

Received: 06 November 2021

Reviewed & Revised: 09/November/2021 to 28/December/2021

Accepted: 30 December 2021

Published: 5 January 2022

Peer-review Method

External peer-review was done through double-blind method.

URL: <https://www.discoveryjournals.org/medicalscience>



This work is licensed under a Creative Commons Attribution 4.0 International License.

Sameera Dronamraju¹, Sourya Acharya², Shraddha Jain³, Charan Bagga⁴, Sunil Kumar⁵

ABSTRACT

Ludwig's angina is a potentially fatal condition that can result from periodontal infections that are not treated promptly. It is uncommon in pregnancy; however, it has been documented. Pregnancy causes cellular metabolic changes in the body along with a higher risk of poor dental hygiene. Tooth decay is more common among pregnant women for a variety of reasons. Dengue infection may precipitate Ludwig's angina in an already predisposed individual due to leukopenia, gingival haemorrhage, compromised immune system, etc. We report a case of a 31-year-old primigravida, with 20 weeks period of gestation, who presented with fever, suprapubic abdominal pain. She was diagnosed with threatened abortion and dengue fever (serological test indicative of IgM positive Dengue) on admission. During the course of hospital stay she developed Ludwig's angina and was treated conservatively with antibiotics and was discharged on 17th day of hospitalisation after complete resolution of symptoms. This case highlights that early detection and prompt intervention in a potentially life-threatening condition like Ludwig's angina may defer interventions like intubation, tracheostomy and surgical drainage.

Keywords: Leukopenia, poor dental hygiene, airway

1. INTRODUCTION

Ludwig's angina was named after Wilhelm Friedrich von Ludwig, a German physician who originally documented the condition as a rapid and usually fatal cellulitis and congestion of the connective tissue structures in the mouth and neck region in 1836. The most life-threatening complication of Ludwig's angina is airway obstruction, which is caused due to expansion of soft tissue edema and also due to shifting of the tongue posteriorly (Saifeldien & Evans, 2004). The submandibular region is the predominant region of infection. The diaphragma oris (mylohyoideus) separates this region into two sections: superiorly, the sublingual space, and inferiorly, the submaxillary space. Most instances of Ludwig's angina have an odontogenic origin, with the second and third molars involved being the most common cause. Dental infection or

abscesses of these two teeth have direct access to submaxillary space and infection of which can spread contiguously to sublingual space. Infection can also spread enclosing the airway by spreading to the pharyngomaxillary and retropharyngeal regions. The aetiology in most cases is odontogenic infection however; other causes are trauma, fractures of the mandible and abscesses in and around the tonsillar fossa (Spitalnic & Sucov, 1995).

Pregnancy causes considerable alterations in the functioning of the body, including a higher risk of poor dental health, dental cavities, and infections. Dental caries and decay is observed more commonly amongst women during pregnancy due to reasons including higher amount of secretions in the mouth which are acidic in nature, dietary habits, and a lack of dental hygiene. Due to an upheaval of the physiological system and sepsis complications, dental caries or unmanaged oral infection can take on life-threatening proportions during pregnancy, with a heightened risk of serious foetal outcomes (Hey Hadavi, 2002).

Dengue fever is a highly endemic tropical infectious disease that is a result of infection with any of the four dengue virus serotypes and is transmitted to humans by female *Aedes* mosquitoes. The severity of dengue disease ranges from a simple fever to dengue haemorrhagic fever and shock syndrome. Classic dengue (CD) can cause leukopenia and haemorrhagic disorders such as purpura and petechiae, bleeding from gums or nose, uterine bleeding, and significant gastrointestinal bleeding, which are usually mild (Khetarpal & Khanna, 2016).

The purpose of this case report is to discuss the possible pathophysiologic factors underlying Ludwig's angina and dengue fever in pregnancy, as well as the need of early detection and intervention.

2. CASE REPORT

A 31-year-old primigravida presented to us with high grade continuous fever with chills since 3 days, bleeding per vagina, suprapubic pain since 2 days associated with abdominal cramps. On admission, blood investigations were done to uncover the source of fever which was positive for dengue IgM serology. Ultrasonographic examination of abdomen was done, and it revealed that the foetus was not viable hence, the pregnancy was terminated. On admission, patient's lab investigations were as follows, hemoglobin-7.1gm %, total leukocyte count-4500 cells/cumm, total platelet count- 31,000 cells/cumm, alanine transaminase-145U/L, aspartate transaminase- 90 U/L, kidney function tests were within normal range. Patient was transfused with packed red cells (PRC), one unit and four units of platelet concentrates in view of low haemoglobin and platelet counts. She was also started on prophylactic antibiotics, antipyretics, analgesics, and other supportive care. After 4 days of hospital stay, patient developed sudden onset gross swelling in the submandibular region causing problem in breathing and deglutition (Fig 1). Ultrasonography of neck and submandibular region was performed which was suggestive of bilateral submandibular gland cellulitis along with changes of reactive lymphadenopathy along the submental, submandibular, and upper jugular lymph nodes (Figure-2a & b).

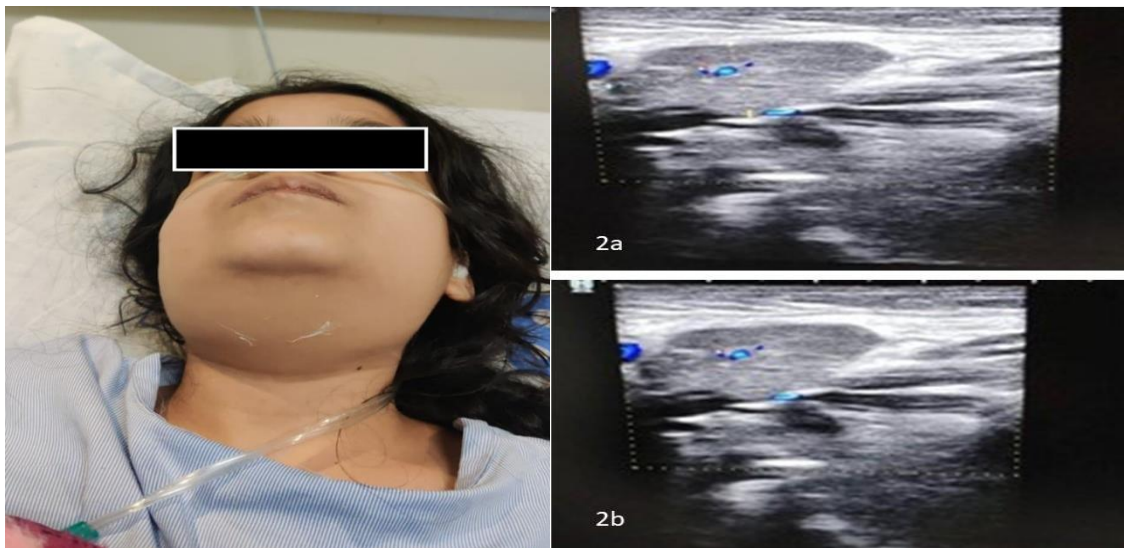


Figure 1 Showing diffuse submandibular oedema

Figure 2a & b Showing enlarged submandibular glands

Patient was kept in propped up position, started on antibiotics Inj.Meropenem 1g I.V. thrice daily for 12 days, Inj.Clindamycin 600mg I.V. twice daily for 12 days, oxygen support, anti-inflammatory, analgesics, and other supportive care. Her vital parameters were monitored regularly along with other relevant laboratory parameters. She showed symptomatic improvement with aggressive

medical management and swelling reduced drastically within 5 days (Figure 3a& b). She was discharged in a vitally stable state on 17th day of hospitalisation.

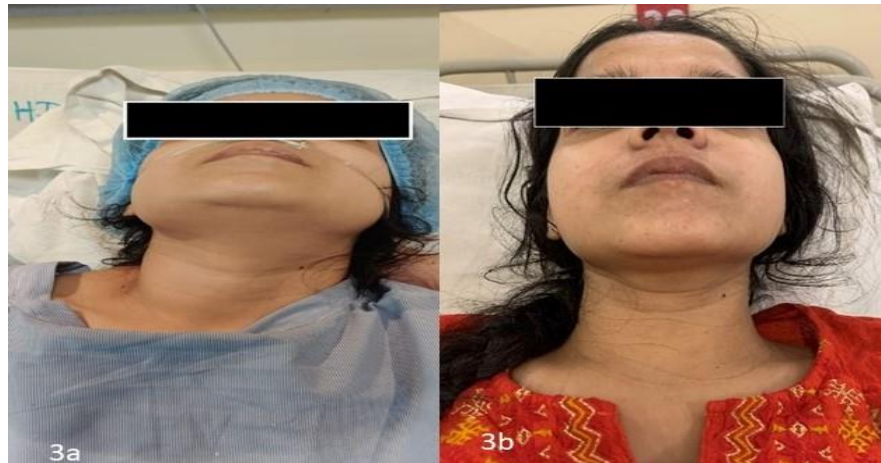

Figure 3a & b taken on day 5 and day 10 after onset of Ludwig's angina showing drastic improvement in swelling.

3. DISCUSSION

Ludwig's angina is most commonly seen in patients who have poor dental hygiene. Ludwig's angina is usually caused by a combination of aerobic and anaerobic bacteria, with the majority of the bacteria being typical oral flora. Malaise, dysphagia, cervical oedema, swelling of tongue, pain, sore throat, restricted movements of neck and stridor suggestive of impending airway restriction characterise the clinical picture (Moreland et al., 1988). Causative agents have been identified as gram-positive cocci like streptococcus viridans, staphylococcus epidermidis and staphylococcus aureus along with anaerobic pathogens such as peptostreptococcus and bacteroides. Early intensive antibiotic therapy, any abscess should be incised and drained, airway management are all essential in the treatment of a patient with Ludwig's angina. The affected tooth or teeth is frequently extracted as well. Intravenous beta lactam antibiotics like penicillin along with antibiotics against anaerobic organisms like clindamycin, or metronidazole are suggested before culture and sensitivity results are obtained. The use of gentamycin is also recommended by certain authors. In recent studies, intravenous steroids have been proposed as a strategy to avoid the requirement for artificial airway (Har et al., 1994).

Pregnancy brings about complex changes in the body, including the oral cavity, many of which are potentially harmful. Every pregnant woman should be advised to seek medical and dental care during antenatal period, as failing to do so can impair the health of both the foetus and mother. Dental care practitioners should be required to receive basic education about the physiologic changes of pregnancy, the use of drugs during pregnancy, and their impact on the delivery of dental treatment (Livingston et al., 1998). Dengue viral infection may predispose the patient to Ludwig's angina by means of a weakened immune system, gingival bleed serving as a base for pathogens, poor oral care, and leukopenia causing infections by commensals.

4. CONCLUSION

There are not many reports of Ludwig's angina associated with dengue fever. Our case report emphasises the need for further research in such cases. Our report also highlights the need for prompt and aggressive management of Ludwig's angina which helps to reduce morbidity and mortality in such cases and abetting the need for invasive procedures like intubation and surgery.

Acknowledgement

We thank the patient and our guides who contributed to the study.

Informed consent

Written & Oral informed consent was obtained from the patient included in the study.

Author contribution

SD, SA, SK and SJ-Concept and writing of the manuscript, CB-Data collection.

Funding

The study did not receive any external funding

Conflict of interests

The authors declare that there are no conflicts of interests.

Data and materials availability

All data associated with this study are present in the paper.

REFERENCES AND NOTES

1. Har-El G, Aroesty JH, Shaha A, Lucente FE. Changing trends in deep neck abscess. A retrospective study of 110 patients. *Oral Surg Oral Med Oral Pathol* 1994; 77:446–50
2. Hey-Hadavi JH. Women's oral health issues: sex differences and clinical implications. *Women's Health Prim Care* 2002; 5(3):189–199.
3. Khetarpal N, Khanna I. Dengue Fever: Causes, Complications, and Vaccine Strategies. *J Immunol Res* 2016; 2016:1–14.
4. Livingston HM, Dellinger TM, Holder R. *Spec Care Dentist* 1998; 18(5):183-8.
5. Moreland LW, Corey J, McKenzie R. *Arch Intern Med* 1988; 148(2):461-6.
6. Saifelddeen K, Evans R. Ludwig's angina. *Emerg Med J* 2004; 21(2):242-3.
7. Spitalnic SJ, Sucov A. Ludwig's angina: Case report and review. *J Emerg Med* 1995; 13:499–503.