



Efficiency of *Taraxacum officinale* leaves extract in alleviating gastric ulcer in male rats

Arwa M Turkistani

Department of Food and Nutrition, King Abdul-Aziz University, Jeddah, Saudi Arabia

Article History

Received: 4 May 2019

Reviewed: 7/May/2019 to 15/June/2019

Accepted: 19 June 2019

Prepared: 28 June 2019

Published: September - October 2019

Citation


Arwa M Turkistani. Efficiency of *Taraxacum officinale* leaves extract in alleviating gastric ulcer in male rats. *Medical Science*, 2019, 23(99), 628-638

Publication License



This work is licensed under a Creative Commons Attribution 4.0 International License.

General Note

 Article is recommended to print as color digital version in recycled paper.

ABSTRACT

The main objective of the current study is to evaluate the potential of *Taraxacum officinale* leaf aqueous extract (TLE) on injury occasioned by ingestion of Non-Steroidal Anti-inflammatory Drugs (NSAIDs), indomethacin (INDO), in Wistar rats. Fifty rats (200-220g) were used for this study. The ulcer was induced by administering 30 mg/kg of the INDO at the last day of the experiment (14 days). The rats were randomly divided into 5 groups. Group I (Contr); rat served as the normal control; group II (INDO) ; ulcer rats, group III; rats received 20 mg/kg Famotidine (FAM) (reference drug), while group IV and group V; rats pretreated with TLE 500 mg/kg and FAM (20 mg/kg)+TLE (500 mg/kg), respectively for 14 days. The rats were sacrificed 4 h post INDO given. The results showed that there were significant decreases in ulcer index, gastric acidity, pepsin activity, gastric oxidative stress biomarkers, serum anti-inflammatory cytokines with a corresponding significant increase in gastric enzyme antioxidant activity and mucin content in pretreated groups compared with INDO group. Histological studies of the gastric walls of pretreated rats showed marked reduction of mucosal injuries in contrast to the INDO group. Results obtained in the present study are suggestive of the fact that TLE contains

antioxidant and anti-inflammatory phytochemical properties that may be pathways for the ameliorative effect of the gastric mucosa injury induced by NSAIDs causing ulcer.

Keywords: *Taraxacum officinale*, Ulcer, NSAIDs, Famotidine, rats.

1. INTRODUCTION

Duodenum and stomach ulcers usually know as gastric ulcer. Incidence of peptic ulcer (PU) is 11-14% in male and 8-11% in female. However, stomach ulcers are seen equally in male and female (Chan and Leung, 2002). Research has shown that 89-95% of gastric ulcers are concomitant with NSAIDs usage and *Helicobacter pylori* (Albaqawi *et al.*, 2017). The imbalance between defensive and offensive factors can be attributed to several reasons including gastric mucus, defensive mucosal factors like prostaglandins, lipid peroxidation, stress, cellular renovation, glycoproteins, mucosal cell shedding, blood flow, gastric acid, mucin and pepsin secretions (Sokic *et al.*, 2007). The use of NSAIDs and *H. pylori* infection account for more than 70% of the causative factor of PU (Balogun *et al.*, 2013). Despite NSAIDs benefits as anti-inflammatory drugs, are such as INDO that has been used to treat arthritic diseases these drugs may cause PU (Jainu and Devi, 2006 and Biplab *et al.*, 2011). In experiments, the INDO is known to cause stomach ulcers and is more likely to cause gastric damage than other commonly used NSAIDs (Khattab *et al.*, 2001).

Current treatment of PU include antacids (non-systemic and systemic) and drugs that decrease secretion of the acid, such as anti-histamine ulcer cure and anti-histamine medicines for *H. pylori* (Perico *et al.*, 2015). These medicines have reduced the morbidity rate, but can cause several side effects, including recurrence of disease, and are often costly (Sultana *et al.*, 2014). Famotidine (FAM) is histamine-2 blockers that lower the amount of acid in the stomach (Paoluzi *et al.*, 1985). It is an anti-ulcre drug that has been widely used in treating gastric and duodenal ulceration. It is poorly absorbed from the lower gastrointestinal tract (Simon *et al.*, 1985).

Investigations on the bioactive components of medical plants reveal the pharmaceutical potential that can lead to their use as cure for diseases (Abdulla *et al.*, 2009). Traditional /alternative type of medicine have utilized natural plants with a great variety of bioactive chemical compounds isolated and characterized for the treatment of diseases (Balasundram *et al.*, 2016). Among these medicinal plants is *Taraxacum officinale* (dandelion) which has been widely used by Ayurvedic physicians (Hu and Kitts, 2005). In folk medicine the plant is used in the treatment of hepatic disorders, inflammation, cancer and widely used as diuretic, cholerectic and digestive stimulants (Berezi *et al.*, 2013).

The bioactive components in the plant include phenolic acid compounds like caffeic acid, chlorogergeric acid, alkaloids such as protopine, cryptopine, tannins (tannic acid). Dandelion leave is richly composed in minerals like iron, calcium, potassium magnesium, phosphorous. Present in the plant also are vitamins A, C, and B-vitamins of thiamine and riboflavin (Amin *et al.*, 2013). Therefore, this research is evaluating the potential effect of TLE on peptic ulcer.

2. MATERIAL AND METHODS

Material

Drugs, kits and chemicals

Indomethacin (Rothacin capsule, 25 mg) and Famotidine 150 mg were purchased from a local pharmacy (Jeddah). Qauantichrom TBARS assay kit required for lipid peroxidation and superoxide dismutase (SOD) assay kit were purchased from BioAssay systems, CA.USA. Chemicals were obtained from Sigma Chemical Co.

Plant material

T. officinale leaves was obtained from a well-known local herbalist in Jeddah, KSA.

Experimental animals

Fifty male albino rats (200-220 g) were purchased from King Fahd Medical Research Center, KAU. Basal diet was provided from Baghafar Company for Pharmaceutical and Chemical, Jeddah, KSA.

Ethical approval

The experimental study was adhering under rules of Candian ethic upon approval for biomedical committee, KFMRC, KAU, KSA.

Methods

T. officinale leaves extraction

The leaves were washed with distilled water to remove all extraneous matters and then sundried in shade for 14 days by constantly turning it to avoid microbes growth. The sun dried leaves was then pulverized to powder, 100 g of the leaf powder was added to 500 ml of distilled water. The mixture was heated and stirred for 1 hour on a hot plate. The decoction was occupied and allowable to cool for 45 minutes at room temp. Filtered twice and then evaporated under pressure in a rotary evaporator (Sigma – Aldrich. USA), to give 19.07 of the aqueous extract. The extract was then frozen and dissolved in distilled water to desired concentration of 500 mg/kg b.wt (Berezi *et al.*, 2019).

Induction of peptic ulcer

Ulceration was done by the INDO (30 mg/kg) ingestion to animals after fasting as described by Sabiua *et al.* (2015). Ulceration lesions had manifested four hours after administration of INDO.

Experimental design

Fifty albino rats with a mean weight (210 ± 10 g) were used in this study.. Rats were distributed to 5 groups (10 rats): Contr; rats given only distilled water. INDO; rats given distilled water intragastrically for 2 weeks before administrated 30 mg/kg INDO, TLE+INDO; rats given the TLE 500 mg/kg/day p.o, for 14 days before an oral dose of INDO. The TLE dose was chosen according to Kasianningsih *et al.* (2011). FAM+ INDO group; rats were given the FAM 20 mg/kg for 14 days before INDO administration and served as a standard drug (Dashputre and Naikwade, 2011). TLE+FAM+INDO group; rats were given the TLE and FAM at the same given dose for 14 days before an oral dose of INDO. After four h of INDO administrated, the rats were sacrificed. Gastric from all rats were dissected out, and their content was evacuated into a centrifuge tube. Cleaned stomach was processed for chemical and histopathological examination.

Quantification of gastric ulceration

The degree of ulceration in all IND - treated rats was quantified using the Szabo and Hollander (1985) method. The Image Pro Express computer system analyzer was used to quantify the gastric interface of each rat. The total area of mucosal damage was calculated as a percentage of the estimated mm square of the total ulcer area. Ulcer index and ulcer inhibition percentage were calculated using the following equations:

Ulcer index (UI) = Ulcerated area / Total area of mucosa X 100

Percentage ulcer inhibition = UI (IND group) – UI (treated group) / UI (IND group) × 100

Gastric mucosal lesion biomarkers

Stomach juice was diluted and centrifuged 10 minutes at 3000 rpm. In biochemical analyses, the supernatant was then used. The gastric juice pH of the was determined by pH meter (Grieve, 2008) [23]. Pepsin activity and mucin concentrations were determined by Sanyal *et al.* (1971). Gastric acidity was detected in the supernatant by the titration of 0.01 NaOH using the reagent Toepfer as an indicator and expressed as mEq / L (Sanyal *et al.*, 1971).

Preparation of gastric homogeneity and testing of oxidative stress biomarkers

Gastric tissue samples (100 mg) were homogenized in 0.1 M PBS ice cold and centrifuged at 3000 rpm for 10 min using a Teflon pestle. The resulting supernatants were frozen at -20 C until used. Lipid peroxidation (MDA) level and the activity of superoxide dismutase (SOD) were measured by using ELISA kits as described in manufacturer's procedures.

Assay serum levels of inflammatory cytokines

Serum samples used to determine interleukin-6 (IL-6) and tumor necrosis factor - α (TNF- α). All procedures have been carried out as described in the instructions of the manufacturer.

Histopathological studies

Fixed gastric tissues by formaldehyde (10%) from each group were stained with Hematoxylin-Eosin (H&E), and then microscopically examined.

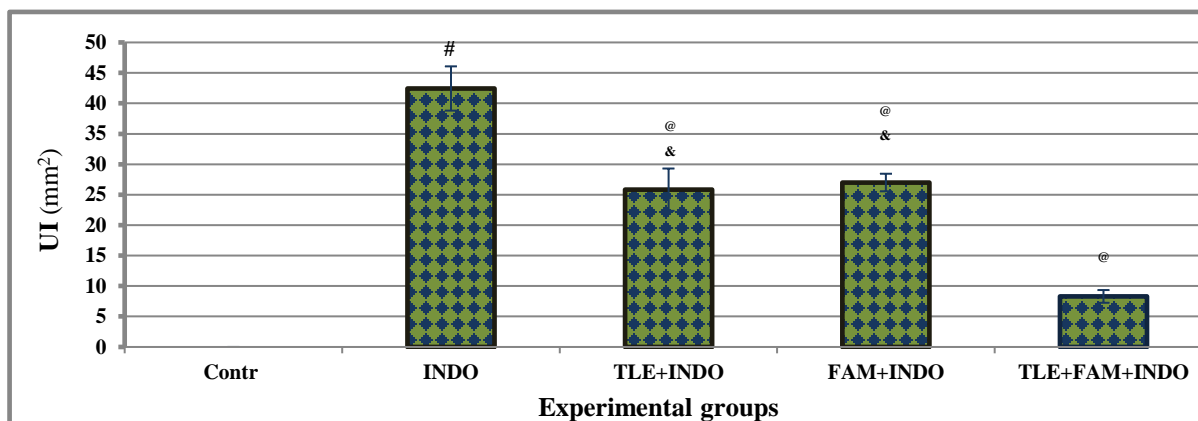
Statistical

The statistics were carried out using SPSS version 22 by one-way analysis of variance ANOVA, LSD. Data were reported as mean \pm SE.

3. RESULTS

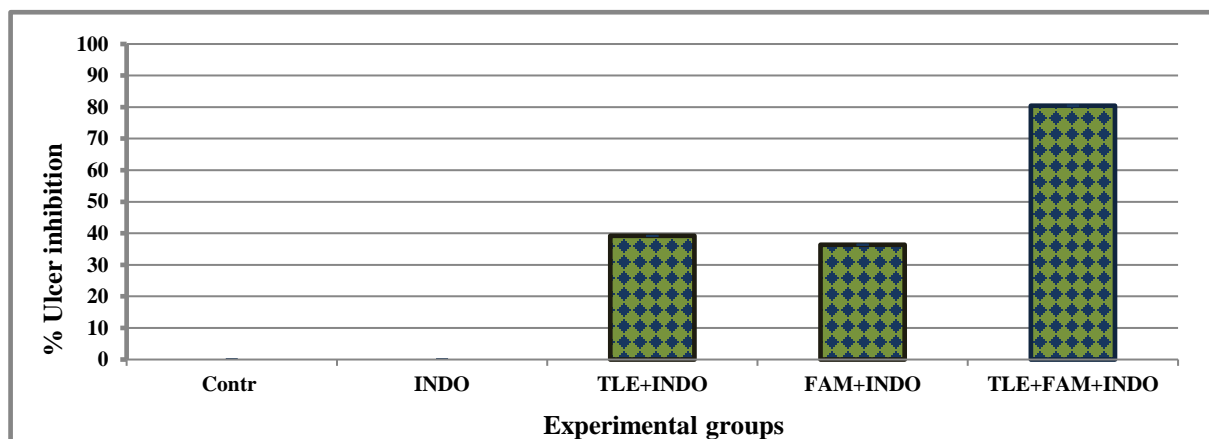
Effect of TLE on UI and % ulcer inhibition in INDO-induced ulceration in rats

Administration INDO induced a significant ($p < 0.001$) increase in the degree of ulceration UI (mm^2) compared with Contr group. The observed increase was significantly attenuated ($p < 0.001$) in TLE, FAM and TLE+FAM pretreated groups with improvement in the % ulcer inhibition compared with INDO group. Pretreatment with both TLE+FAM exerted more potent efficacy in the modulation of UI and greater gastroprotective effect of ulcerated rats, the % ulcer inhibition was (80.44%), (Figure.1 and Figure. 2).



Data are represented as mean \pm SME (n=10 rats). # significant compared with Contr group, @ significant compared with INDO group, \$ significant between TLE+INDO and FAM+INDO groups, & significant compared with TLE+FAM+INDO group.

Figure 1 Effect of TLF on UI against INDO-induced ulceration in rats

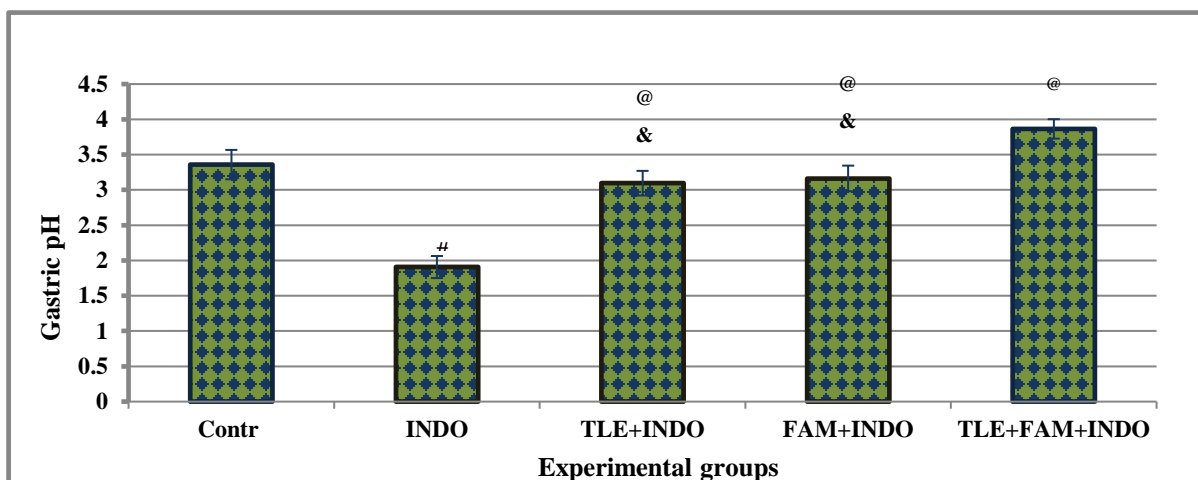


Data are represented as mean \pm SME (n=10 rats). # significant compared with Contr group, @ significant compared with INDO group, \$ significant between TLE+INDO and FAM+INDO groups, & significant compared with TLE+FAM+INDO group.

Figure 2 Effect of TLF on % ulcer inhibition against INDO-induced ulceration in rats

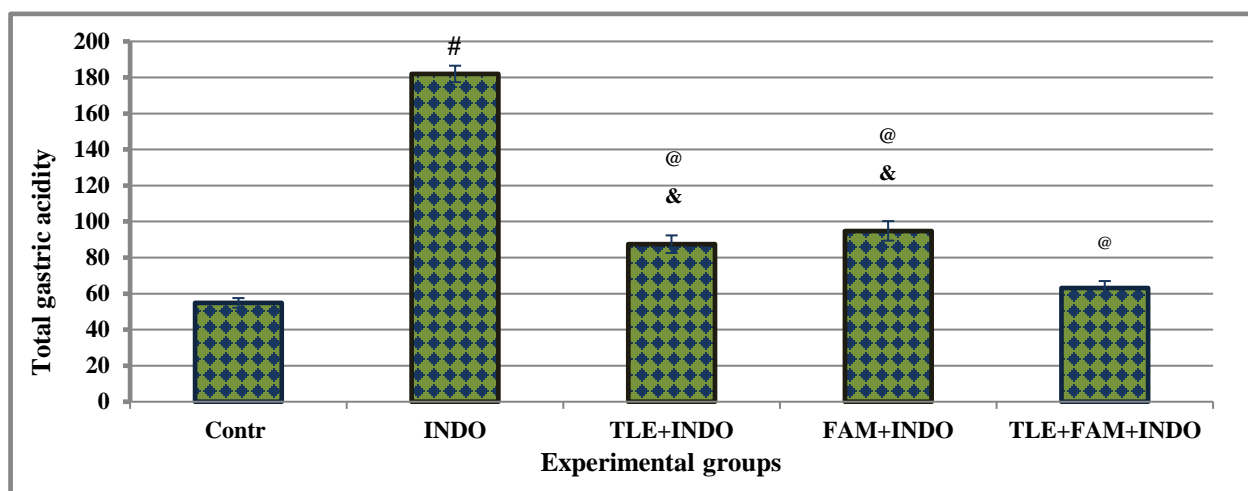
Effect of TLE on gastric secretions parameters in INDO-induced ulceration in rats

Administration of INDO induced a significant ($p < 0.001$) decrease in gastric pH with a corresponding significant ($p < 0.001$) increase in total gastric acidity compared with Contr group. Pretreatment with TLE, FAM and TLE+FAM in ulcerated rats produced significant elevated in the pH level with significant decline in gastric acidity compared to INDO. There were no significant changes between TLE+INDO and FAM+ INDO. On the other hand, pretreatment with both TLE+FAM to ulcerated rats revealed significant difference compared with either TLE+INDO or FAM+ INDO alone (Figure.3 and Figure. 4).



Data are represented as mean \pm SME (n=10 rats). # significant compared with Contr group, @ significant compared with INDO group, \$ significant between TLE+INDO and FAM+INDO groups, & significant compared with TLE+FAM+INDO group.

Figure 3 Effect of TLF on gastric pH against INDO-induced ulceration in rats



Data are represented as mean \pm SME (n=10 rats). # significant compared with Contr group, @ significant compared with INDO group, \$ significant between TLE+INDO and FAM+INDO groups, & significant compared with TLE+FAM+INDO group.

Figure 4 Effect of TLF on total gastric acidity against INDO-induced ulceration in rats

Oral administration of rats with INDO significantly ($p < 0.001$) increase pepsin activity and significantly ($p < 0.001$) decrease mucin content of gastric juice compared with Contr rats. Pretreatment with TLE, FAM and TLE+FAM in ulcerated rats revealed significant decrease in the pepsin activity with significant increase in mucin content compared with INDO group. There were no significant changes between TLE+INDO and FAM+ INDO. However, pretreatment with both TLE+FAM to ulcerated rats exerted significant difference compared with either TLE+INDO or FAM+ INDO alone Table 1.

Table 1 Effect of TLF on gastric pepsin activity and mucin content against INDO-induced ulceration in rats

Experimental groups	Pepsin activity ($\mu\text{g/ml}$)	Mucin content ($\mu\text{g/ml}$)
Contr	95.96 \pm 3.14	381.2 \pm 3.03
INDO	277.99 \pm 4.21 ^a	193.0 \pm 2.25 ^a
TLE + INDO	111.90 \pm 3.12 ^{b, d}	335.2 \pm 2.89 ^{b, d}
FAM+ INDO	120.10 \pm 2.96 ^{b, d}	332.7 \pm 2.67 ^{b, d}

TLE+ FAM+ INDO	104.70 ± 2.88 ^b	366.6 ± 2.90 ^b
----------------	----------------------------	---------------------------

Data are represented as mean ±SME (n=10 rats). ^a significant compared with Contr group, ^b significant compared with INDO group, ^c significant between TLE+INDO and FAM+INDO groups, ^d significant compared with TLE+FAM+INDO group.

Effect of *T. officinale* on gastric oxidative status in INDO-induced ulceration in rats

Administration of INDO induced a significant ($p < 0.001$) increase in gastric MDA content with a corresponding significant ($p < 0.001$) decrease in gastric SOD activity compared with Contr group. Pretreatment with TLE, FAM and TLE+FAM in ulcerated rats produced significant ($p < 0.001$) decrease in the gastric MDA content with significant ($p < 0.001$) increase in gastric SOD activity compared with INDO group. There were significant changes between TLE+INDO and FAM+ INDO. On the other hand, pretreatment with both TLE+FAM to ulcerated rats revealed significant difference compared with FAM+ INDO Table 2.

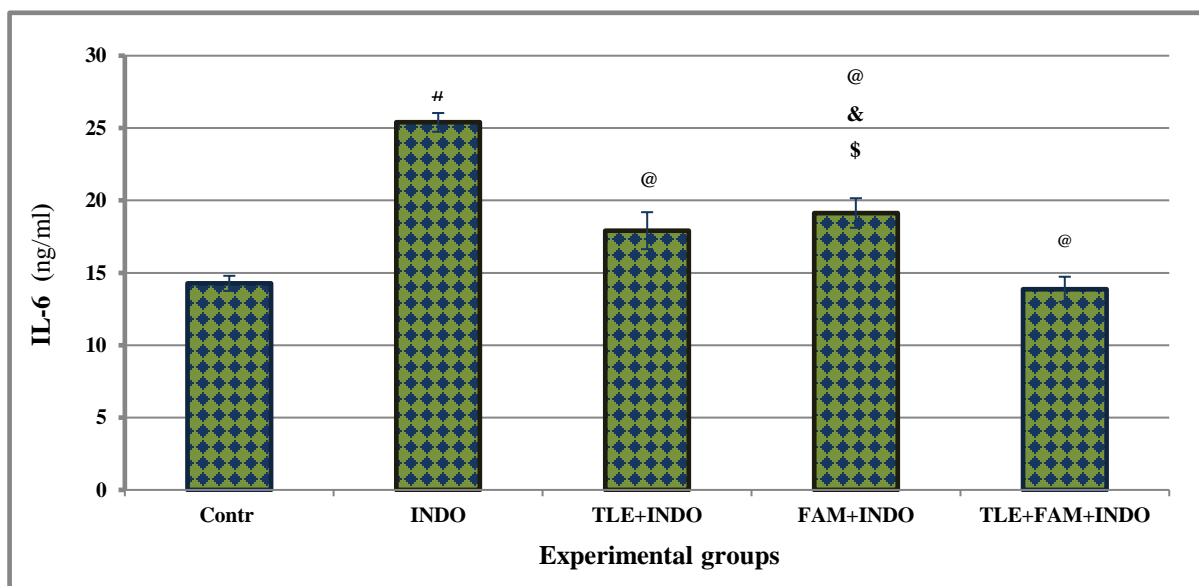
Table 2 Effect of TLF on serum inflammatory cytokines against INDO-induced ulceration in rats

Experimental groups	MDA (μ mol/mg tissue)	SOD (μ mol/mg tissue)
Contr	0.257 ± 0.011	70.94 ± 2.18
INDO	1.033 ± 0.080 ^a	44.68 ± 1.52 ^a
TLE + INDO	0.336 ± 0.029 ^b	68.80 ± 2.72 ^b
FAM+ INDO	0.482 ± 0.039 ^{b, d, c}	56.64 ± 2.39 ^{b, d, c}
TLE+ FAM+ INDO	0.264 ± 0.008 ^b	71.91 ± 2.05 ^b

Data are represented as mean ±SME (n=10 rats). ^a significant compared with Contr group, ^b significant compared with INDO group, ^c significant between TLE+INDO and FAM+INDO groups, ^d significant compared with TLE+FAM+INDO group.

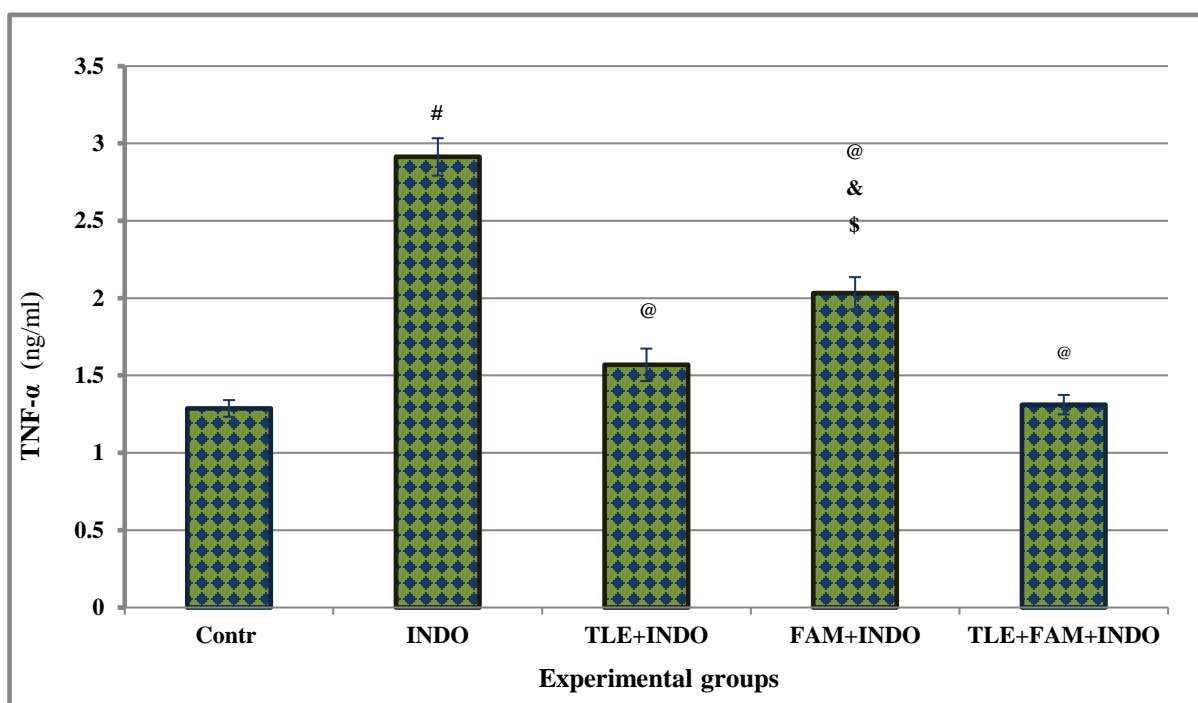
Effect of TLE on serum cytokines in INDO-induced ulceration in rats

Administration of INDO induced a significant ($p < 0.001$) elevate in serum TNF- α and IL-6 levels compared with Contr rats. Rats pretreated with TLE, FAM and TLE+FAM in ulcerated rats produced significant ($p < 0.001$) decrease in the serum inflammatory cytokines TNF- α and IL-6 compared with INDO. There were significant changes between TLE+INDO and FAM+ INDO. On the other hand, pretreatment with both TLE+FAM to ulcerated rats revealed significant differences compared with FAM+ INDO group Figure 5 and Figure.6.



Data are represented as mean ±SME (n=10 rats). [#] significant compared with Contr group, [@] significant compared with INDO group, ^{\$} significant between TLE+INDO and FAM+INDO groups, [&] significant compared with TLE+FAM+INDO group.

Figure 5 Effect of TLF on serum IL-6 against INDO-induced ulceration in rats



Data are represented as mean \pm SME (n=10 rats). # significant compared with Contr group, @ significant compared with INDO group, \$ significant between TLE+INDO and FAM+INDO groups, & significant compared with TLE+FAM+INDO group.

Figure 6 Effect of TLF on serum TNF- α against INDO-induced ulceration in rats

Effect of *T. officinale* on the gastric tissue histopathological changes detected by H&E staining in INDO-induced ulceration in rats

Figure 7 A showed Contr fundic mucosa luminal epithelium rich in blood vessels and lymphocytes, with crowded mucosal crypts in lamina propria. A layer of muscularis mucosa separated the lamina propria and submuco. The parietal cells had central rounded nuclei and eosinophilic cytoplasm. Variable grades of mucosal injuries were showed in INDO ulcerated group Figures 7 B and C, it loss of architecture of epithelium with extreme damage in the gastric epithelium, mononuclear cellular infiltrations, gastric necrotic lesions are seen in the mucosal layer.

Photomicrography of gastric section of Contr rat showed normal glandular fundic mucosa and parietal cells (P) had central rounded nuclei and eosinophilic cytoplasm. Notice: rich blood vessels (arrows), and lymphocytes crowded mucosal crypts in lamina propria (LP) [Fig. A]. The INDO ulcerated rats showed loss of architecture of epithelium and gastric necrotic lesions (star) with severe destruction in the surface epithelium (arrows) [Fig. B] Notice. The dead cells with acidophilic cytoplasm are in the damaged glandular area. Mononuclear cellular infiltrations (small arrows) are seen in the deep mucosal layer and necrotic superficial epithelium (large arrows) [Fig. C]. The TLE+INDO pretreated group showed improve in the gastric mucosa, there were vacuolization (V) of some cells with slightly dilated and congested in the basal parts of the glands (arrows) [Fig. D]. In the FAN+INDO pretreated group showed improvement in the gastric mucosa, slightly cellular infiltration in the lumina propria (arrows) with slightly dilated and congested capillaries (star) [Fig. E]. In TLE+FAN+INDO pretreated group a section showed normal glandular fundic mucosa of the stomach (Fig. F).

The TLE+INDO pretreated group showed improve in the gastric mucosa, with slightly vacuolization of some cells, dilated and congested in the basal parts of the glands (arrows) Figure 7.D. In the FAN+INDO pretreated group the gastric section showed improvement in the gastric mucosa, slightly cellular infiltration in the lumina propria and congested capillaries Figure 7.E. On the other hand pretreatment of INDO ingested rats with in TLE+FAN resulted in nearly complete protection and normal glandular fundic mucosa of the stomach near to the Contr rats. Therefore, it showed stronger protection action compared to pretreatment with either TLE or FAN alone Figure 7. F.

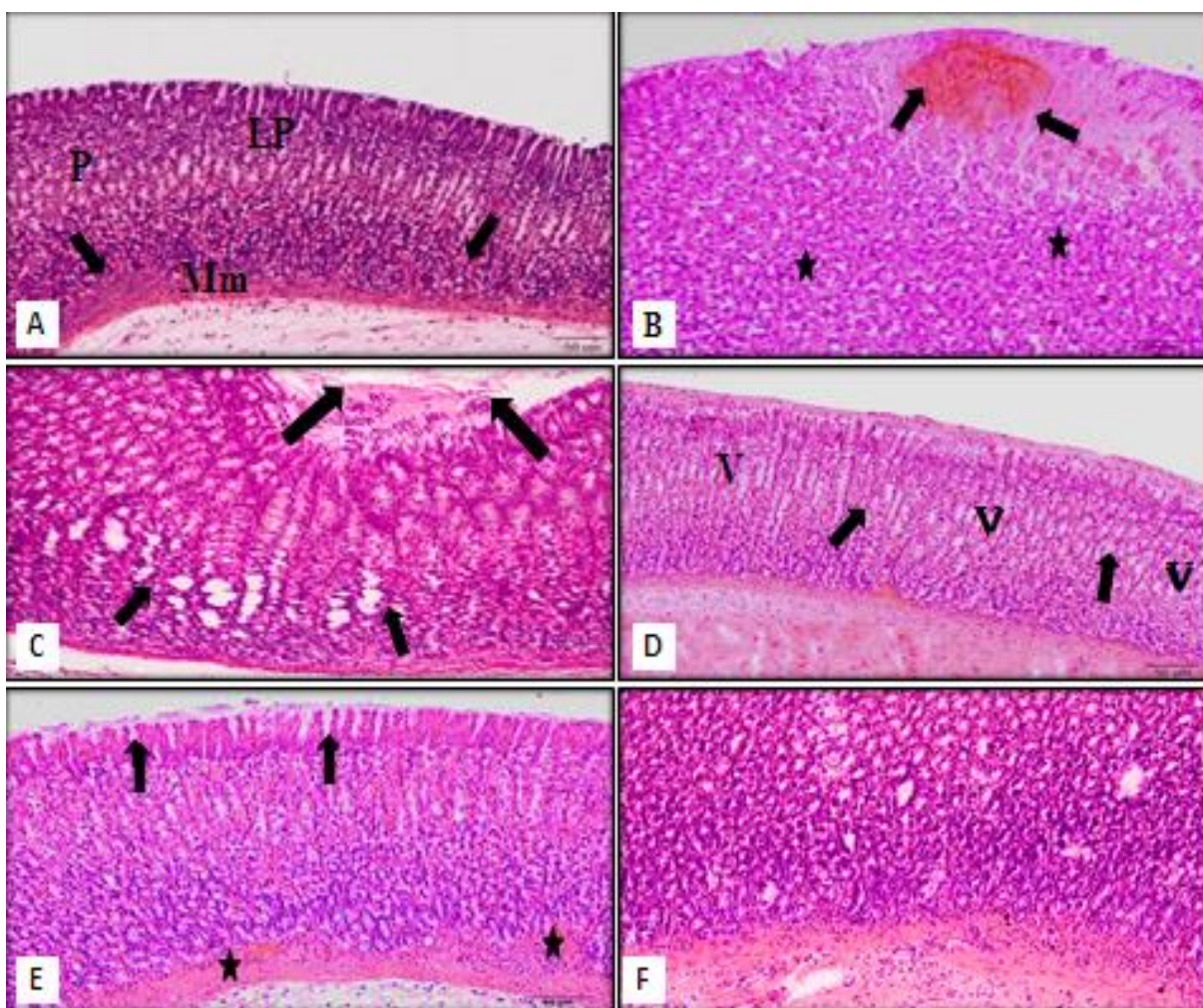


Figure 7 Effect of *T. officinale* on the gastric tissue histopathological changes detected by H&E staining in INDO-induced ulceration in rats (High power magnification).

4. DISCUSSION

Medical plants such as *T. officinale* are known to contain phytochemicals such as flavonoids, phenols, saponins, tannins, alkaloids and glycosides (Grieve, 2008). Flavonoids are important in increasing the synthesis of prostaglandin and decarboxylase (Borrelli and Izzo, 2000). Tannins have been reported to prevent ulcer by improving vasoconstriction effects (Aguwa and Nwako, 1988). The present study has shown that the aqueous extract of *T. officinale* that contain these phytochemicals are believed to be strongly linked to the anti-ulcer benefits.

The NSAIDs like INDO administered at a dose of 30 mg/kg are capable of inducing gastric ulcer. Indomethacin is a potent inhibitor of the biosynthesis of prostaglandin (Sabia *et al.*, 2015). Prostaglandins are known to be actively involved in maintaining the integrity of the gastric mucosa. Prostaglandins are produced by two enzymes, cyclooxygenase (COX); COX-1 and COX-2. NSAID's are COX inhibitors, they work by decreasing the production of prostaglandin which is meant to protect the lining of the stomach and intestines from the damaging effects of acids, stimulate mucus and bicarbonate output (Hogan *et al.*, 1994), and promote blood clotting by activating platelets (Goulart *et al.*, 2005).

Biochemical stomach secretion analysis (for gastric volume, pH, pepsin and bicarbonate) and stomach mucosal integrity are usually used to determine its status after exposure to pharmacological agents (Biplab *et al.*, 2011). The results of the current study showed significant increases in the total gastric acidity and ulcer index with a significant decrease in pH in the ulcerated group compared to the control group that could be attributed to either free radicals formation or prostaglandin synthesis inhibition that impaired gastroprotection and increased secretion of gastric acid, which are important events in mucosal ulceration etiology (Lüllmann *et al.*, 2000). Pretreatment with TLE, FAM and their combination showed marked improvement on the gastric lesions and gastric oxidative stress biomarkers as well as TNF- α and IL-6 compared with INDO ulcerated rats. The most effective protective pretreatment was seen in the rats co-pretreated with both TLE and FAM compared with other pretreated groups.

Famotidine is an antagonist of the histamine-2 receptor. It is employed to treat peptic ulcer (Lin, 1991). It is a proton pump inhibitor, which suppresses gastric acid secretion by specific inhibition of the gastric H⁺/K⁺/ATPase enzyme at the secretory surface of the gastric parietal cells (Myers, 2006).

The ulcer healing observed in the present study are similar to those previously reported by Razavi *et al.* (2014). The anti-ulcer effect of FAM could be explained by its interfering in the gastric acid secretion, such as H₂ antagonists and proton pump inhibitors (Myers, 2006). Furthermore, Ramchandran and Dhanaraju (2011) demonstrated that FAM treatment completely suppressed gastric acid secretion, greatly reduced erosive lesion formation, prevented the progression of these stomach ulcer lesions that is accompanied by an increase in plasma gastrin levels, stomach blood flow and a significant reduction in interleukin-1beta plasma levels.

In this study, the increased pepsin activity in indomethacin-ulcerated rats combined with the decreased mucin secretion this is due to the hydrophobicity alteration and reduced protective capacity of the mucosal membrane against hemorrhagic erosion, resulting in tissue damage (Repetto and Llesuy, 2002). Pretreatment with the reference drug or plant extract facilitated the process of ulcer healing associated with reduced pepsin activity and increased levels of mucin in the stomach mucosa. Which in turn encouraged rapid wound healing of the ulcerated areas of the mucosal epithelia and shielded the gastrointestinal membrane, thus may be due to the active compound in the plant extract (Grieve, 2008). This suggests that the extract increased mucus secretory potential and recommends their important role in the process of ulcer healing. Plant extract showed prominently healing of mucosa epithelia at a dose of 500 mg/kg and a good comparison with the reference medicine used.

Oxidative stress is a vital aspect in the pathogenesis of several diseases including ulcer (Chattopadhyay *et al.*, 2006). Antioxidants have been reported to take effects of necrotic agents against gastric mucosa. They help to enhance the body defense system by inhibiting the injury that can be caused to the stomach (Satich *et al.*, 2011). *T. officinale* aqueous extract has been shown to contain antioxidants, which are likely to have imparted this ameliorating effect on injury accessioned by the NSAID.

In the recent study, the SOD activity reduced as well as the concentration of MDA increased in the stomach of INDO-ulcerated rats which is a manifestation of enabled lipid peroxidation and free radicals production that resulting in mucosal damage. Free radicals prevent antioxidant enzyme activity and initiate lipid peroxidation, a significant event in the indomethacin toxicity mechanism (Sahoo and Kanhar, 2017). However, the significantly decreased level of MDA associated with a significant increase in the SOD activity in pretreated rats with TLE and FAM are obvious indication of their antiperoxidative and therefore antioxidant activity. The TNF- α and IL-6 are pro-inflammatory cytokines that during ulcerative stress are increasingly secreted by macrophages (Hamaguchi *et al.*, 2001). They stimulate neutrophil infiltration into the gastrointestinal mucosa (Wei *et al.*, 2003). Inhibition of IL-6 and TNF- α infiltration inhibits the destruction of tissues by reactive species of oxygen (Kwiecien *et al.*, 2002). The INDO increased TNF- α and IL-6 significantly compared to the control group in the study. This finding coincided with Jeon *et al.* (2008) who documented that the pretreatment of rats with TLE at 500 mg/kg was significantly reduced serum anti-inflammatory cytokines concentration. Anti-inflammatory activity of TLE could be attributed to the suppression of anti-inflammatory cytokines production, which affects the myeloperoxidase catalytic reactions (Koh *et al.*, 2010).

Furthermore In the present study, the protective effect of TLE confirmed by histopathological examination, the results showing prevention of mucosal lesions, the TLE pretreated rats showed improvements in their examined stomach tissues. This extract's anti-ulcer activity is possibly due to the extract's antioxidant activity. In addition, gastric protection and anti-ulcerogenic activity of flavonoids have been reported (Mahmood *et al.*, 2010).

Flavonoids compounds have antioxidant and free radicals scavenging activities that have been attributed to their large content of polyphenolic compounds, particular flavonoids, phenolic acids and tannins (Hammad, 2013). The phytochemical screening of TLE revealed the presence of phenols, steroids, tannins, saponins and alkaloids. It indicated that the plant has the potency of scavenging free radicals (Berezi *et al.*, 2019).

5. CONCLUSION

From the results obtained in this present study, it can be conclude that the aqueous extract of *T. officinale* leaves have antiulcerogenic properties. The antioxidants present in the plant extract may be responsible for the ameliorating effect on the gastric mucosa due to the inhibition of acid secretion. A reduction of the ulcer areas in the gastric wall as well as, inhibition of leucocyte infiltration of the mucosal layers thus lead to the improvement in the ulcer healing process.

Conflicts of interest

The authors declare that there are no conflicts of interest.

REFERENCE

1. Abdulla MA, Ali HM, Ahmed KAA, et al. Evaluation of the anti-ulcer activities of *Morus alba* extracts in experimentally-induced gastric ulcer in rats. *BioMed Res Inter* 2009; 20:35–9.
2. Aguwa CN, Nwako SO. Preliminary studies on the root extract of *Nauclealati folia* Smith for anti-ulcer properties. *Nigeria J of Pharm Sci* 1988; 4: 16–23.
3. Albaqawi ASB, El-fetoh NMA, Alanazi RFA, et al. Profile of peptic ulcer disease and its risk factors in Arar. *North Saudi Arabia. Electron Phys* 2017; 9: 5740–5.
4. Amin M, Sarohney SS, Jassal MMS. Qualitative and quantitative analysis of phytochemicals of *Taraxacum officinale*. *Woodpecker J of Pharm and Pharmacol* 2013; 2: 001–5.
5. Balasundram N, Sundram K, Samman S. Phenolic compounds in plants and agri-industrial by-products: Antioxidant activity, occurrence, and potential uses. *Food Chem* 2016; 99: 191–203.
6. Balogun ME, Oji JO, Besong EE, et al. Anti-ulcer activity of aqueous leaf extract of *Nauclea latifolia* (rubiaceae) on indomethacin-induced gastric ulcer in rats. *African J of Biotechnol* 2013; 12:5080–6.
7. Berezi EP, Monago CC, Adelagun ROA. Hematological profile of rats treated with aqueous extracts of Dandelion (*Taraxacum officinale*) against carbon tetrachloride (CCl₄) toxicity. *Inter J Biochemist and Biotechnol* 2013; 2: 263–7.
8. Berezi EP, Uwakwe AA, Monago-Ighorodje CC, et al. Efficiency of *Taraxacum officinale* (Dandelion) leaf extract in alleviating ulcer occasioned by long ingestion of Non-Steroidal Anti-inflammatory Drug (NSAID) in Wister rats. *J of Biotechnol and Biochemist* 2019; 9:29–36.
9. Biplab A, Sudhir KY, Kshama R, et al. Black tea and theaflavins assist healing of indomethacin-induced gastric ulceration in mice by antioxidative action. *Evid Based Complem Alt Med* 2011; 11:11–22.
10. Borrelli F, Izzo A. The plant kingdom as a source of anti-ulcer remedies. *Phytotherapy Res* 2000; 14: 581–91.
11. Chan FK, Leung WK. Peptic-ulcer disease. *Lancet* 2002; 360:933–41.
12. Chattopadhyay I, Bandyopadhyay U, Biswas K, et al. Indomethacin inactivates gastric peroxidase to induce reactiveoxygen-mediated gastric mucosal injury and curcumin protects it by preventing peroxidase inactivation and scavenging reactive oxygen. *Free Radic Biol Med* 2006; 40:1397–408.
13. Dashputre NL, Naikwade NS. Evaluation of anti-ulcer activity of methanolic extract of *Abutilon indicum* Linn leaves in experimental rats. *Inter J Pharm Sci Drug Res* 2011; 3:97–100.
14. Goulart YCF, Sela VR, Obici R, et al. Evaluation of gastric anti-ulcer activity in a hydro-ethanolic extract from *Kielmeyera coricea*. *Brazilian Achiev for Biol and Technol* 2005; 48: 211–6.
15. Grieve M. Dandelion (*Taraxacum officinale* weber). A modern herbal. *Botanical.Asia J of Pharmacol and Clin Res* 2008; 35:1–10.
16. Hamaguchi M, Watanabe T, Higuchi A, et al. Mechanisms and roles of neutrophil infiltration in stress-induced gastric injury in rats. *Dig Dis Sci* 2001; 46:2708–15.
17. Hammad M. Biological activities of the hydro-alcoholic and aqueous extracts of *Achillea biebersteinii* Afan. (Asteraceae) grown in Jordan. *African J of Pharmacy and Pharmacol* 2013; 7:1686–94.
18. Hogan DL, Ainsworth MA, Ibensberg JI. Gastro duodenal bicarbonate secretions eliminate. *Phrenol and Therapeut* 1994; 8:475–9.
19. Hu C, Kitts DD. Dandelion (*Taraxacum officinale*) flower extract suppresses both reactive oxygen species and nitric oxide and prevents lipid oxidation in vitro. *Phytomed* 2005; 12: 588–97.
20. Jainu M, Devi C. The Gastroprotective action of *Cissus quadrangularis* extract against NSAID-induced gastric ulcer: the role of proinflammatory cytokines and oxidative damage. *Chem Biol Interact* 2006; 161: 262–70.
21. Jeon HJ, Kang HJ, Jung HJ, et al. Anti-inflammatory activity of *Taraxacum officinale*. *J. Ethnopharmacol* 2008; 115: 82–8.
22. Kasianningsih S, Rivanti E, Ratih H P, et al. *Taraxacum officinale* leaves ethanolic extract as immunostimulatory agent for reducing side effect of doxorubicin in Sprague Dawley rats *Indonesian J of Cancer Chemoprevent* 2011; 2:135-40.
23. Khattab MM, Gad MZ, Abdallah D. Protective role of nitric oxide in indomethacin-induced gastric ulceration by a mechanism independent of gastric acid secretion. *Pharmacol Res* 2001; 43:463–7.
24. Koh YJ, Cha DS, Ko JS, et al. Anti-inflammatory effect of *Taraxacum officinale* leaves on lipopolysaccharide-induced inflammatory responses in RAW 264.7 cells. *J Med Food* 2010; 13:870–8.
25. Kwiecien S, Brzozowski T, Konturek SJ. Effects of reactive oxygen species on gastric mucosa in various models of mucosal injury. *J Physiol Pharmacol* 2002; 53:39–50.
26. Lin JH. Pharmacokinetic and pharmacodynamics properties of histamine H₂-receptor antagonists. relationship between intrinsic potency and effective plasma concentrations. *Clin Pharmacokinet* 1991; 20:218–36.

27. Lüllmann H, Mohr K, Ziegler A, Bieger D. 2nd ed. Thieme Stuttgart; New York: Coloratlas of Pharmacol 2000; p: 166.
28. Mahmood AA, Mariod F, Al-Bayaty FH, Abdel-Wahab SI. Anti-ulcerogenic experimentally – induced gastric lesions in rats. *J of Med Plant Res* 2010; 4: 685 –91.
29. Myers D. H2 Receptor antagonists. *J Exot Pet Med* 2006; 15:150–2.
30. Paoluzi P, Torsoli A, Bianchi N, Porro G. Famotidine in the treatment of gastric ulcer. Results of a multicenter double-blind controlled study. *Digestion* 1985; 32: 38–44.
31. Perico LL, Heredia-vieira SC, Beserra FP, et al. Does the gastroprotective action of a medicinal plant ensure healing effects? An integrative study of the biological effects of *Serjania marginata* Casar. (Sapindaceae) in rats. *J of Ethnopharmacol* 2015; 172: 312–24.
32. Ramchandran G, Dhanaraju MD. Evaluation of gastric and duodenal antiulcer activity of famotidine formulation in experimental animals. *J of Pharmacol and Toxicol* 2011; 6:189– 95.
33. Razavi M, Nyamathulla S, Karimian H, Noordin MI. Novel swellable polymer of orchidaceae family for gastroretentive drug delivery of famotidine. *Drug Des Devel Ther* 2014; 8:1315–29.
34. Repetto MG, Llesuy SF. Antioxidant properties of natural compounds used in popular medicine for gastric ulcers. *Braz J Med Biol* 2002; 35:523–34.
35. Sabiua S, GarubaT, SunmonucT, et al. Indomethacin-induced gastric ulceration in rats: Protective roles of *Spondias mombin* and *Ficus exasperate*. *Toxicol Report* 2015; 2 :261–7.
36. Sahoo AK, Kanhar S. Antioxidant and antiulcer potential of hydrolea *Zeylanica* (L.) vahl against gastric ulcers in rats. *Inter J of Comp and Altern Med* 2017; 10: 120–9.
37. Sanyal AR, Denath OK, Bhattacharya SK, Gode KD. The effect of cyproheptadine on gastric acidity, in: C.J. Pfeiffer (Ed.), *Peptic ulcer*, Scandinavian University Books, Munksgoard 1971; 312–8.
38. Satich R, Sahu R, Nataraja K. Anti-ulcer and antioxidant activity of ethanolic extract of *Passiflora foetida* L. *Indian J of Pharmacol* 2011; 3: 336- 9.
39. Simon B, Damman HG, Jakob G. Famotidine versus ranitidine for the short term treatment of duodenal ulcer. *Digest* 1985; 32: 32–7.
40. Sokic MA, Krstic M, Popovic D. Role of *Helicobacter pylori* infection and use of NSAIDs in the etiopathogenesis of upper gastrointestinal bleeding. *Acta Chir Iugosl* 2007; 54:51–62.
41. Sultana S, Akram M, Asif MH, Akhtar N. Complementary and Alternative Approaches to treat peptic ulcer. *Inter Res J of Phar* 2014; 5:353– 9.
42. Szabo S, Hollander D. Pathways of gastrointestinal protection and repair: mechanisms of action of sucralfate. *Am J Med* 1985; 86:23–31.
43. Wei XM, Heywood GJ, Di Girolamo N, Thomas PS. Nicorandil inhibits the release of TNF alpha from a lymphocyte cell line and peripheral blood lymphocytes.. *Int. Immunopharmacol* 2003; 3:1581–8.