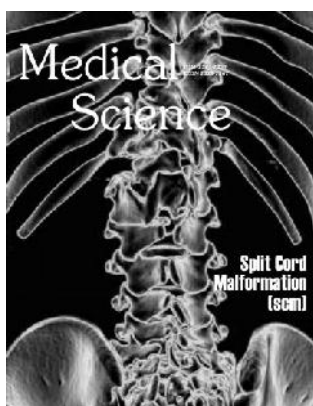


Medical Science

About the Cover



Descriptions of split cord malformation (SCM) appeared in the medical literature as early as the 17th century (Barkovich, 1990; Bademci, 2006). Several terminologies were in vogue in literature like “diastematomyelia” and “diplomyelia” with a poor distinction. In 1992, Pang and colleagues proposed a unified theory attributing both type I and type II SCM to a single error in embryogenesis: adhesion between the ectoderm and endoderm leading to a persistent neurenteric canal (Beardmore et al, 1958; Pang et al, 1992). Increasingly SCM is being recognised as a cause of Tethered Cord Syndrome (TCS). We present an interesting case of SCM in a male infant, who presented to our institute as a part of medical tourism in India and discuss briefly its clinical presentation, illustration of surgical technique and avoidance of complications (Upadhyay PK, Pandey P, Mishra Y, Gupta U, Pandey S. Split Cord Malformation – Illustration and precautions in surgical technique and complication avoidance. *Medical Science*, 2016, 20(77), 21-27).

A detailed account of heat stroke

Muhammad Nehal Nadir, Bharti Kachela, Neeha Nadir, Zehra Khan

Heat stroke is defined as hyperthermia or exceptionally high fever which occurs due to soaring body temperatures above 41.1°C (106°F) associated with pathophysiological changes that result in neurologic, multi-organ system dysfunction and death. Characterized by CNS dysfunction, it is also responsible for a number of organs malfunctioning of the body and is basically of two types. Various pathophysiological changes occur in the body which consequently leads to a heat stroke. The Iranian method has shown marked reduction in mortality among all other cooling techniques. A number of risk factors are responsible for aggravating the condition however proper knowledge and awareness can help in avoiding and managing a heat stroke. This article discusses heat stroke and its management in detail.

Medical Science, 2016, 20(77), 1-4

PERSPECTIVE

Ayurvedic Naturoceuticals: Evidence Based Data and Clinical Implications. Part I

Neil K Agarwal, Shashi K Agarwal

Ayurveda is a several millennia old Indian medical system. Data from historical, epidemiological, experimental and clinical studies provide compelling evidence that several ayurvedic neutraceuticals, not only provide prophylactic and therapeutic activity against several diseases, but may actually improve general health and promote longevity. These include herbs, oils, spices, plants, minerals and trace amounts of heavy metals. Although widely used in India, firm scientific evidence for their effectiveness has been lacking due to the small and often improperly done clinical trials. However more expansive and rigorous research is now being done, providing evidence based data on the effectiveness and safety of these natural products. In the United States, Ayurvedic medications are regulated as dietary supplements. The first part of this four part series reviews seven popular ayurvedic naturoceuticals or ayurceuticals.

Medical Science, 2016, 20(77), 5-9

Ayurvedic Naturoceuticals: Evidence Based Data and Clinical Implications. Part II

Neil K Agarwal, Shashi K Agarwal

Ayurveda is a several millennia old Indian medical system. Data from experimental, epidemiological and clinical studies provide compelling evidence that several ayurvedic neutraceuticals not only provide prophylactic and therapeutic activity against several diseases, but may actually improve general health and promote longevity. These include herbs, oils, spices, plants, minerals and trace amounts of heavy metals. Although widely used in India, firm scientific evidence for their effectiveness has been lacking due to the small and often improperly done clinical trials. However more expansive and rigorous research is now being done, providing evidence based data on the effectiveness and safety of these natural products. In the United States, ayurvedic medications are regulated as dietary supplements. The second part of this four part series reviews another seven ayurvedic supplements.

Medical Science, 2016, 20(77), 10-15

CASE STUDY

Case of primary hyperparathyroidism presenting with ADHD (Attention Deficit Hyperactivity Disorder)-like symptoms

Alyahyawi Huda Yahya

The paper presents the case report of a 14-year-old adolescent boy initially presented to the psychiatric clinic with behavioral symptoms consistent with those associated with Attention Deficit Hyperactivity Disorder (ADHD) including inability to concentrate, hyperactivity, and poor school performance. Based on DSM-IV-TR (The Diagnostic and Statistical Manual of Mental Disorders, 4th Edition, Text Revision) criteria, ADHD diagnosis was confirmed and he was started on medication treatment without a significant improvement of symptoms. More than two years later, an elevated parathyroid hormone, hypercalcemia, and hypophosphatemia led to a diagnosis of Primary Hyperparathyroidism. After clinical, laboratory and radiological examination, Adenoma of the right inferior parathyroid gland was successfully diagnosed and surgically removed. Upon regulating the patient's calcium levels, his mood, concentration, and cognitive function were back to baseline 6 months post operation. The common theme of resolving ADHD symptoms upon regulating the calcium levels, highlights the importance of careful evaluation of all possible secondary causes of Attention Deficit Hyperactivity Disorder (ADHD) during the Initial psychiatric assessment and at each follow-up visit, especially when multiple medications have been ineffective or poor response is noticed.

Medical Science, 2016, 20(77), 16-20

SURGICAL GUIDELINES

Split Cord Malformation – Illustration and precautions in surgical technique and complication avoidance

Upadhyay PK, Pandey P, Mishra Y, Gupta U, Pandey S

Descriptions of split cord malformation (SCM) appeared in the medical literature as early as the 17th century (Barkovich, 1990; Bademci, 2006). Several terminologies were in vogue in literature like "diastematomyelia" and "diplomylia" with a poor distinction. In 1992, Pang and

colleagues proposed a unified theory attributing both type I and type II SCM to a single error in embryogenesis: adhesion between the ectoderm and endoderm leading to a persistent neurenteric canal (Beardmore et al, 1958; Pang et al, 1992). Increasingly SCM is being recognised as a cause of Tethered Cord Syndrome (TCS). We present an interesting case of SCM in a male infant, who presented to our institute as a part of medical tourism in India and discuss briefly it's clinical presentation, illustration of surgical technique and avoidance of complications.

