

## Drug Discovery

### To Cite:

Mishael UE, Bassey EI, Edem G. Effect of Ethanolic leaf extract of *Jatropha gossypifolia* on the Stomach of Wistar Rats. *Drug Discovery* 2026; 20: e5dd3043

doi: <https://doi.org/10.54905/diss.v20i45.e5dd3043>

### Author Affiliation:

<sup>1</sup>Department of Anatomy, Faculty of Basic Medical Sciences, University of Uyo, main Campus, 520003, Uyo, Akwa Ibom State, Nigeria, E-mail; unwanamishael@gmail.com, Phone Number; +2348137855509

<sup>2</sup>Department of Anatomy, Faculty of Basic Medical Sciences, University of Uyo Main Campus, 520003, Uyo, Akwa Ibom State, Nigeria; E-mail; enoobongbassey@uniuyo.edu.ng, Phone Number; +2347036807334

<sup>3</sup>Department of Anatomy, Faculty of Basic Medical Sciences, University of Uyo Main Campus, 520003, Uyo, Akwa Ibom State, Nigeria; E-mail; gabrieledem@uniuyo.edu.ng, Phone Number; +2348084478479

### Peer-Review History

Received: 29 July 2025

Reviewed & Revised: 12/August/2025 to 16/January/2026

Accepted: 30 January 2026

Published: 18 February 2026

### Peer-Review Model

External peer-review was done through double-blind method.

Drug Discovery

pISSN 2278–540X; eISSN 2278–5396



© The Author(s) 2026. Open Access. This article is licensed under a [Creative Commons Attribution License 4.0 \(CC BY 4.0\)](https://creativecommons.org/licenses/by/4.0/), which permits use, sharing, adaptation, distribution and reproduction in any medium or format, as long as you give appropriate credit to the original author(s) and the source, provide a link to the Creative Commons license, and indicate if changes were made. To view a copy of this license, visit <http://creativecommons.org/licenses/by/4.0/>.

# Effect of Ethanolic leaf extract of *Jatropha gossypifolia* on the Stomach of Wistar Rats

Unwana E Mishael<sup>1</sup>, Eno-obong I Bassey<sup>2</sup>, Gabriel Edem<sup>3</sup>

## ABSTRACT

The study investigated the effects of the administration of ethanolic leaf extract of *Jatropha gossypifolia*, on the stomachs of twenty adult male Wistar rats, which were divided into four groups of five (weighing 80-120g). Five hundred grams of air-dried *Jatropha gossypifolia* leaves were cold macerated in 70 % ethanol, filtered, and concentrated using a water bath. Thirty mice (18-25 g) were used in the acute toxicity study. The LD<sub>50</sub> was carried out to determine doses represented as low dose (86.60 mg/kg), middle dose (173.21mg/kg) and high dose (259.81mg/kg) of the *Jatropha gossypifolia* leaf extract. The animals were administered the extract orally using an orogastric tube for 28 days. After sacrifice the stomachs were harvested and fixed in 10% buffered formalin, dehydrated in alcohol, cleared in xylene, infiltrated in molten paraffin wax, and embedded. The tissues were processed to paraffin sections, cut at 5 microns, stained in Haematoxylin and Eosin staining technique and observed Histopathologically under light microscope. The photomicrograph of tissues in group 1 revealed standard epithelial lining, gastric glands, muscularis mucosa, submucosa, and muscularis externa. The photomicrograph of group 2 revealed mild erosion on columnar cells, normal gastric glands, and submucosa. Photomicrograph of group 3 revealed severe epithelial eroding, zymogenic cell edema, and submucosa degeneration while those in group 4 revealed severe epithelial erosion, severe submucosa degeneration with loss of connective tissue components. Severity was dependent on the dose of administration. All data were analyzed using descriptive statistics and ANOVA (SPSS version), with result significance at  $p < 0.05$ . In conclusion, it is shown that the ethanolic leaf extract of *Jatropha gossypifolia* posed a degree of pathological condition on the stomach, including epithelial erosion, submucosal degeneration, and loss of connective tissue components.

**Keywords:** *Jatropha gossypifolia*, Ethanolic, Histopathology, Stomach

## 1. INTRODUCTION

The plant *Jatropha gossypifolia* belongs to the family of Euphorbiaceae. The Habitat is forest and farmland. The plant is commonly found in tropical and subtropical environments. It is widely called Bellyache bush in English language, in French language “Faux manioc” in Yoruba language “Lapalapa pupa” in Igbo language, “Oluluidu” in Ibibio language “Eto-eko-obionsit”, and among Pidgin speakers we have “Hospital too far”. *Jatropha gossypifolia*, is a traditional medicinal plant which is

primarily used throughout Africa. *Jatropha* is also an ornamental plant, a perimeter fencing plant in the rural areas and a leafy vegetable for soups and stews (Sabandar *et al.*, 2013; Utshudi *et al.*, 2022). The roots, stems, seeds, and leaves of the plant can be used for purge, fever, blood tonic, and antioxidant (Qinghua *et al.* 2019; Gabriel & Idu, 2021). The seed oil of the plant is used as an ingredient in the treatment of rheumatism, itching and parasitic diseases including fever and gonorrhoea (Fapanusi and Adewole *et al.*, 2021). The plant *Jatropha gossypifolia* is a diuretic agent and a mouthwash. The leaf is a hemostatic agent, while the bark can be used as a fish poison (Felix-Silva *et al.*, 2004). Toxicity study carried out using ethanolic extract of *Jatropha gossypifolia* was observed to be abundant in toxalbumins, toxalbumin can inhibit protein synthesis, cause agglutinations to blood cell types. *Jatropha*, also contain a lipid resin complex that can cause dermatitis (Mariz *et al.*, 2012; Abdelgadir & Staden, 2013) glomerular distortion, and increased urinary spaces in the kidney, as well as elevated serum urea level (Dhale & Birari, 2010; Fapanusi & Adewole, 2021)

Generally, *Jatropha gossypifolia* is of great importance in most typical Nigerian homes, in the treatment of various ailments such as anemia, diabetes, malaria, and as well as blood pressure control and this research will provide an understanding of the effect of *Jatropha gossypifolia* on the stomach of Wistar rats with regards to its beneficial role or toxicity. The stomach is an organ found in the digestive tract of higher animals. Its primary functions are digestion of food, secretion of gastric juices, and secretion of gastric hormones (Singh, 2011; Antony, 2013).

The layers of the stomach play a major function in secretion, support, protection, contraction, and relaxation of the muscle. The stomach also has distinctive cells such as the mucous neck cell (produces protective mucous), parietal cell (produces HCL), zymogenic cells (secrete pepsinogen), gastric cells (it produces the peptide hormone gastrin), stem cells, and enterochromaffin cells (it produces the histamine, which is essential in the release of stomach acid) (Singh, 2011). The general objective of this research work was to study the effects of the administration of the ethanolic leaf extract of *Jatropha gossypifolia*.

The specific objectives were:

- To determine the effect of *Jatropha gossypifolia* on the body weight of the experimental animals
- To observe and study the histomorphology of the stomach of Wistar rats after the administration

## 2. MATERIALS AND METHODS

### 2.1. Materials

The leaves of *Jatropha gossypifolia*, collected from the University of Uyo main campus were identified and authenticated by a botanist in the Department of Pharmacy.

### 2.2. Source and Maintenance of Animals

Twenty (20) matured and sexually active male Wistar rats, weighing 80-120 g is used for this study. We kept the rats in the animal house of the Faculty of Basic Medical Sciences in clean and spacious cages, with beddings made from saw particles. The researchers exposed the rats to twelve hours light and twelve hours dark cycle at a room temperature of 27°C - 30°C. They animals ate a standard rat pelletized diet (Vital Feed Growers, Grand Cereals Nigeria Ltd) and water.

### 2.3. Extract Preparation

The leaves of *Jatropha gossypifolia* plant was washed by the researchers, chopped into tiny bits and pounded. After pounding, it was dried at room temperature and measured. The dried leaves were extracted by dissolving in 70% ethanol for 72 hours. We let the mixture stand for 30 minutes, then evaporated the solution over a water bath at 40°C and stored in containers in the refrigerator at 4°C (Azwanida, 2015).

### 2.4. Test Solution and Administration

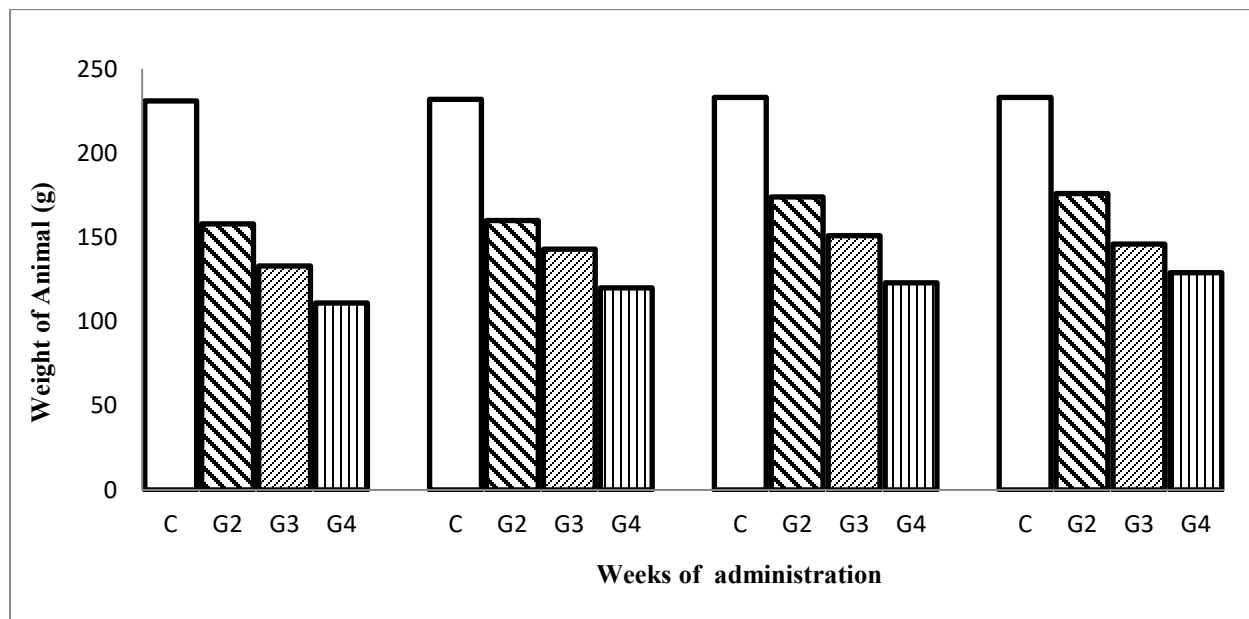
This study applied Lorke's method to determine the median lethal dose (LD<sub>50</sub>). The plant extract showed an LD<sub>50</sub> of 866.03mg/kg. The doses of the extract given was calculated as 10% of 866.03 (86.60), 20% of 866.03 (173.21) and 30% of 866.03 (259.81) mg/kg respectively. We administered the plant extract orally using orogastric tube for 28 days in the morning.

### 2.5. Histological Studies

At the end of the experiment the rats were drowsed with chloroform, the abdomen was carefully opened and the specimen (stomach) collected. Samples were fixed in 10% neutral buffered formalin and prepared for Histological Studies.

### 3. RESULTS

The result of the weight of the animals in different groups over weeks of administration is presented in a bar chart as shown in Fig.1. Results obtained from histological sections of animals in control (distilled water), group 2 (86.60mg/kg of *Jatropha*, group 3 (173.21mg/kg of *Jatropha*), and group 4 (259.81mg/kg of *Jatropha*) in Haematoxylin & Eosin (H & E)  $\times 100$  are shown in Figure 2.



**Figure 1:** C: Distilled water; G2: 86.60mg/kg of *Jatropha*; G3: 173.21mg/kg of *Jatropha*; G4: 259.81mg/kg of *Jatropha*.

### 4. DISCUSSION

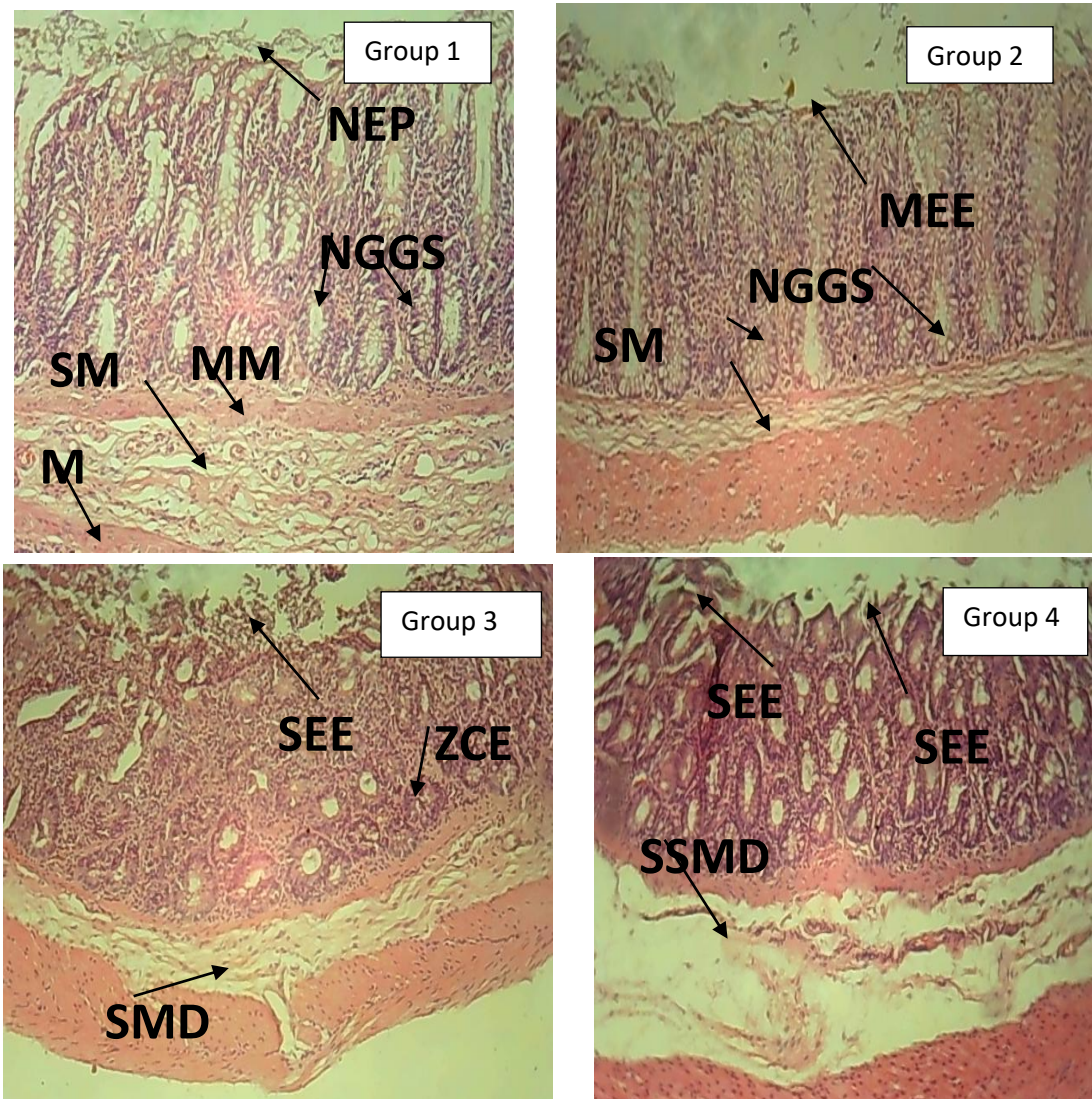
The plant extract of *Jatropha gossypifolia* exhibited moderate toxicity; it is dose-dependent. This is reflected by its low LD<sub>50</sub>, since it has been reported that any compound or drug with an oral LD<sub>50</sub> estimate of more than 500 mg/kg could be considered of moderate toxicity. The extract treatment resulted in no significant change in the body weight of the rats compared to the control group. In the low-dose group (86.60 mg/kg), the rats showed no statistically significant body weight gain from week three onwards compared to the first two weeks of administration. From week three, body weight gain in group three (173.21mg/kg) was not statistically significant compared to the baseline established in the first two weeks. Rats in group four, which received the high-dose extract (259.81mg/kg), exhibited no significant change in body weight.

The extract may induce a sense of satiety or affect appetite regulation, leading to lower calorie consumption. It could also be due to the absence of anorectic and lipolytic properties in this plant (Gabriel & Idu, 2021; Kagadi *et al.*, 2019; Adeniyi *et al.*, 2025). The extract of *Jatropha gossypifolia* caused severe damage, characterized by profound erosion of the epithelial layer, extensive submucosal degeneration, and depletion of connective tissue, when administered a high dose of the extract. The distortion in the mucosa and submucosa layer indicates that the extract contains phytotoxins (toxalbumins).

Phytotoxins are proteolytic enzymes, which are able to breakdown critical proteins and caused the accumulation of ammonia (Mariz *et al.*, 2010; Mariz *et al.*, 2011; Abdelgadir & Stadem, 2013). Photomicrograph of the stomach of rats that were administered medium dose of the extract showed severe erosion of the columnar cells, zymogenic cell edema and submucosal degeneration. The finding suggests that the extract was able to penetrate the layers of the stomach, destroying glands found deep in the mucosa layer. The destruction of the gastric chief cells-which secrete the pepsin and renin, leads to protein accumulation due to inadequate protein digestion.

Fewer symptoms were observed in the group two rats that receive low dose of the extract. The photomicrographs of group two showed minimal damage to the epithelial cells, with normal morphology of the gastric glands. Photomicrographs of the control group showed normal epithelial lining, gastric glands, muscularis mucosa and submucosal. Alteration of the mucosa layer of the stomach will lead to destruction of the gastric glands, impairing mucous secretion and reducing or inhibiting the secretion of hydrochloric acid, intrinsic factor and pepsinogen; the lack of hydrochloric acid would prevent the conversion of pepsinogen to pepsin. Protein

accumulation causes edema, which can lead to prolonged retention and improper of digestion of food. Submucosa degeneration causes the depletion of connective tissue components, including blood vessels, nerves, and immune cells (lymphocytes and microphages).



**Figure 2:** Photomicrograph of the longitudinal section of the stomach in normal control (Group 1), showing normal epithelial lining (NEP), normal gastric glands (NGGS), muscularis mucosa (MM), submucosa (SM) and muscularis externa (M). Group 2 showing mild erosion of the simple columnar cells epithelium (MEE), normal gastric glands (NGGS) and submucosa (SM). Group 3, showing severe erosion of the simple columnar cells of the epithelium (SEE), zymogenic cell edema (ZCE) and submucosal degeneration (SMD). Group 4, showing severe erosion of the columnar cells of the epithelium (SEE) and severe submucosal degeneration (SSMD) with loss of connective tissue components. H & E x 100

Reviews and experimental studies have demonstrated that consumption of the plant *Jatropha gossypifolia* has adverse effect on the Wister rats (Ananta *et al.*, 2015; Qinghua *et al.*, 2019; Kagadi *et al.*, 2019).

## 5. CONCLUSION

The present study demonstrates that *Jatropha gossypifolia* leaf extract possesses moderate toxicity and lacks significant anorectic and lipolytic activities. Although the extract is relatively safe at lower doses (86.60mg/kg), higher doses (173.21mg/kg upward) cause severe damage to the gastric mucosa in Wistar rats. Histopathological analysis revealed severe epithelial erosion, submucosal degeneration, and loss of connective tissue components, with the severity of damage exhibiting a dose- and duration-dependent relationship.

### Acknowledgements

I appreciate the staff of the Department of Anatomy and the Faculty of Basic Medical Sciences, University of Uyo for the technical support, and granting me access to their research facility.

### Author Contributions:

The research work was jointly carried out by the three authors, Unwana Mishael, Eno-obong Bassey, and Gabriel Edem.

The design of the study, research and manuscript writing is by Unwana Mishael.

The statistical analysis, and photomicrograph taking is by Gabriel Edem.

The interpretation of the result, discussion, and proof reading is by Eno-obong Bassey.

### Ethical Approval

In this article, the animal regulations & plant guidelines are followed as per the ethical committee guidelines of Department of Anatomy, Faculty of Basic Medical Sciences, University of Uyo, main Campus, 520003, Uyo, Akwa Ibom State, Nigeria; the authors observed the effect of ethanolic leaf extract of *Jatropha gossypifolia* on the stomach of wistar rats. The Animal ethical guidelines are followed in the study for observation, identification & experimentation. Also, the ethical guidelines for plants & plant materials are followed in the study for observation, identification & experimentation. The study was approved by the Faculty of Basic Medical Sciences Research and Ethical Committee (Ethical approval number UU\_FBMSREC\_2017\_011).

### Informed Consent

Not applicable.

### Conflicts of interests

The authors declare that they have no conflicts of interests, competing financial interests or personal relationships that could have influenced the work reported in this paper.

### Funding

This research did not receive any external funding like specific grant from funding agencies in the public, commercial, or nonprofit sectors.

### Data and materials availability

All data associated with this study will be available based on the reasonable request to corresponding author.

## REFERENCES

1. Abdelgadir HA, Staden JV. Ethnobotany, Ethnopharmacology and Toxicity of *Jatropha curcas* L. (Euphorbiaceae): A Review, South African Journal of Botany 2013;88:204-218. doi: 10.1016/j.sajb.2013.07.021.
2. Adeniyi OV, Adedayo MR, Afe AI. Effects of dietary *Jatropha gossypifolia* leaves extract on growth performance, antioxidant capacity, immune response, and disease resistance of African sharptooth catfish (*Clarias gariepinus*) infected with *Aeromonas hydrophila*. Journal of Applied Aquaculture 2025;37(2):156-181. doi: 10.1080/10454438.2382431.
3. Antony LM. Junqueira's Basic Histology Text and Atlas. 2013. 13th ed. McGraw-Hill Education, Asia, Vol 6, pp.205-236.
4. Azwanida NN. A Review on the Extraction Methods Used in Medicinal Plants, Principle, Strength and Limitation. Medicinal and Aromatic Plants 2015;4(3):196. doi: 10-4172/2167.0412.1000196.
5. Dhale DA. & Birari AB. Preliminary Screening of antimicrobial and Phytochemical Studies of *Jatropha gossypifolia* Linn. Research in Science and Technology 2010;2(7):24-28.
6. Fapanusi F, Adewole A. Phytochemical Constituents and Antibacterial Activities of *Jatropha Curcas* and *Jatropha gossypifolia* leaves. International journal of Women in Technical Education and Employment (IJOWITED) 2021;2(2):146-155.
7. Felix-Silva J, Giodani RB, Antonio da Silva-Jr A, Zucolotto SM, & Matheus de Freitas Fernandes-Pedrosa. *Jatropha gossypifolia* L. (Euphorbiaceae): A Review of Traditional Uses, Phytochemistry Pharmacology and Toxicology of This

- Medicinal Plant Evidence. Based Complementary and Alternative Medicine 2004;369204. doi: 10.1155/2014/369204.
8. Gabriel BO, Idu MD. Anti-diuretic and anti-glycemic properties of *Jatropha g.* leave extract on Wistar rats. Clinical phytoscience 2021;7:93. doi: 10.1186/s40816-021-00329-6.
  9. Kagadi NM., Ladda PL, Naikwade NS, Shikalgar TS & Ptil SS. A Review of Hepatoprotective Medicinal Plants. Journal of Pharmaceutical Sciences Review and Research. 2019;56(1):122-132.
  10. Mariz SR, Cerqueira, GS, Araújo WC, Dantas JG, Ramalho JA. Chronic toxicologic study of the ethanolic extract of the aerial parts of *Jatropha gossypifolia* in rats. RevistaBrasil de Farmacog 2012;22:663-668. doi: 10.1590/S0102-695X2005000024.
  11. Mariz SRI, Borges ACR, Melo-Diniz, MFF, Medeiros IA. Possibilidades terapeuticas eriscos toxicologicos de *Jatropha gossypifolia* L.: uma revisao narrative. Revista Brasileira De Plantas Medicinaias 2010;12(3):346-357. doi: 10.1590/S1516-0572201000300013
  12. Qinghua W, Patocka J, Nepovimova E, Kuca K. *Jatropha gossypifolia* L. and its biologically active metabolites: A mini review journal of Ethnopharmacology 2019;234:197-203. doi: 10.1016/j.jep.2019.01.022.
  13. Sabandar CW, Ahmat N, Jaafar FM, Sahidin I. Medicinal property, phytochemistry and pharmacology of several *Jatropha* species (Euphorbiaceae): a review. Phytochemistry 2013;85:7-29. doi: 10.1016/j.phytochem.2012.10.009.
  14. Singh I. Textbook of Human Histology. 2011; 6th ed. Jaypee Brothers Medicals Publishers, New Delhi.
  15. Utshudi AL, Oleko RO, Kayembe CT, Onautshu DO, Kitete EM, Lengbye EM, Mbala BM, Mpiana PT. Phytochemistry and Ethnopharmacology of *Jatropha gossypifolia* L. (Euphorbiaceae): Bioactivities and Future Direction. International journal of Pathogen Research 2022;10(2):29-43. doi: 109734/ijpr/2022/v10i230246.