

Reversal of ischemia and pain in a patient of Subclavian Artery Stenosis: A rare Case

Vivek chakole¹, Jeshnu Tople¹, Vidur Mago^{2*}

To Cite:

Chakole V, Tople J, Mago V. Reversal of ischemia and pain in a patient of Subclavian Artery Stenosis: A rare Case. *Medical Science* 2022; 26: ms542e2553.

doi: <https://doi.org/10.54905/disssi/v26i130/ms542e2553>

Authors' Affiliation:

¹Professor, Department of Anaesthesiology, Jawaharlal Nehru Medical College, Datta Meghe Institute of Medical Sciences (Deemed to be University), Wardha, Maharashtra, India

²Post Graduate Resident, Department of Anaesthesiology, Jawaharlal Nehru Medical College, Datta Meghe Institute of Medical Sciences (Deemed to be University), Wardha, Maharashtra, India

*Corresponding author

Post Graduate Resident, Department of Anaesthesiology, Jawaharlal Nehru Medical College, Datta Meghe Institute of Medical Sciences (Deemed to be University), Wardha, Maharashtra, India

Peer-Review History

Received: 29 October 2022

Reviewed & Revised: 02/November/2022 to 28/November/2022

Accepted: 10 December 2022

Published: 20 December 2022

Peer-review Method

External peer-review was done through double-blind method.

URL: <https://www.discoveryjournals.org/medicallscience>



This work is licensed under a Creative Commons Attribution 4.0 International License.

ABSTRACT

The wide array of peripheral arterial diseases (PAD) includes stenosis of the subclavian artery. Estimated around 2percent of the total population is thought to have subclavian artery, which is the incidence of subclavian artery stenosis. Individuals more than 70 years of age have a 15% prevalence of PAD. Five percent of patients will have critical limb ischemia out of this group and roughly a quarter of them will need revascularization. Left subclavian artery stenosis affects almost fifty percent of patients with documented peripheral arterial disease, accounting for 30% of all cases. Due to the sluggish course of the disease, a large population of individuals is asymptomatic. Once the vessel diameter has shrunk by 50% at the luminal end, symptoms frequently start to show. The disease is most prevalent in the sixth to seventh decade of life, with symptoms ranging from central nervous system to the circulatory system including pain, swelling, numbness, ischemic changes and vertigo to name a few. The primary method for diagnosing and treating sympathetically sustained pain disorders involving the upper extremities, such as complicated regional pain syndrome, is stellate ganglion block, a minimally invasive operation (CRPS). The stellate ganglion block can be a great treatment modality in multiple neuropathic pain disorders, including ischemic neuropathies, painful viral infections such as herpes zoster (shingles), early PHN and post-radiation neuritis, where it has been found effective in pain relief.

Keywords: PHN, CRPS, ischemia, Subclavian Artery Stenosis

1. INTRODUCTION

The presentation of multiple symptomatic conditions like Hand claudication, cerebral hypo-perfusion, peripheral embolization and ischemia of digits can all find their origin in subclavian and innominate artery peripheral arterial disease, which is a kind of stenosis of the subclavian artery (PAD). Those patients undergone through coronary artery bypass graft or axillo femoral bypass can PAD coronary steal occur in lower extremity claudication or upper extremity. Physical examination should identify any extremities with marked differences in systolic blood pressure between the ipsilateral and contralateral of greater than 10mmHg. In severe situations, ischemia of digits has been demonstrated and the affected limb might sense chilly to the touch. Patients

with associated risk factors for PAD, such as smoking, metabolic disorders like diabetes mellitus, hypertensive disorders, hyperlipidemia, peripheral arterial artery disease of the lower extremity (Caesar-Peterson et al., 2022) and more, are typically encountered in their later ages of life. Subclavian artery stenosis has a significant morbidity rate because it causes symptoms of ischemia in the heart, brain and upper extremities. Atherosclerosis is the most prominent cause. Arteritis, radiation-induced inflammation, fibromuscular dysplasia, other conditions like neurofibromatosis and compression syndromes are among the other causes (Bando et al., 2019).

The stellate ganglion block is a well-known and effective procedure for diagnosing and treating sympathetically sustained pain in the head, neck and upper extremities. In the body, the stellate ganglion transports sympathetic fibres to and from the head, neck and upper extremities. The stellate ganglion is usually discovered on the transverse process of the seventh cervical vertebra, anterior to the neck of the first rib and just lateral to the lat longus colli muscle's lateral border. In addition to relieving pain and enhancing blood flow, blocking the stellate ganglion has been effective in treating vascular insufficiency disorders such as persistent angina pectoris, Raynaud's disease, vasospasm of the vessels, certain conditions like frostbite which is caused due to cold temperature, vasospasm and embolic vascular illness or any occlusive disorder. Last but not least, since the sympathetic fibers regulate sweating, stellate ganglion block has been found to be effective in reducing hyperhidrosis.

The subclavian artery stenosis results in artery wall remodeling and lipid buildup in the tunica media. As the process progresses, the lumen of the artery narrows, causing calcification of the arterial wall (Martínez Moreno et al., 2019), the brachiocephalic arteries, including the innominate and subclavian, can also be affected by vascular diseases including Takayasu arteritis and giant cell arteritis. Unifocal or multifocal brachiocephalic atherosclerosis can occur. The disease of brachiocephalic arteries resulting in Transient ischemic attack (TIA), or it could also present claudication or ischemia of the upper extremity and vertebrobasilar insufficiency. Stellate ganglion block which is a kind of cervical sympathetic ganglion blockade, with the help of local anesthetic agents results in cessation of sympathetic discharge leading to peripheral vessel dilatation, preventing the progression of obstruction. Thus, stellate ganglion block offers a very effective alternative treatment in treating the symptoms arising due to narrowing and ischemic changes (Kim et al., 2018).

2. CASE REPORT

A 44-year-old female from Wardha, complaints of numbness in the left upper limb for eight days along with pain and swelling over the left upper limb for eight days. The pain was insidious in onset and was a severe pricking type of pain continuous in nature. There was associated swelling and numbness present. The patient also complains of bluish discoloration of the digits of the left hand. There is no history of (H/o) any systemic or local trauma present. No history of hypertension/diabetes mellitus/seizure disorder/respiratory illness. No h/o any substance abuse. Vitals, Blood pressure-136/80mm of heart rate 82/min SpO₂ 98% on room air, G.C.S 15/15.

The patient took NSAIDs, which provided only slight relief. Despite visiting numerous physician-patient with no outcome, which patient came to our pain clinic where thorough history and examination were done along with routine investigation. All other differentials for the symptoms were excluded. The patient then underwent Angiography after which a diagnosis of Subclavian artery stenosis was made. The patient was then explained about various modalities like angioplasty and also, she was given the alternative of stellate ganglion block as a means of short-term relief, which was explained to the patient. As Angioplasty is an invasive procedure patient opted for a stellate ganglion block for pain relief.

Preoperatively the patient was comprehensively explained about the procedure including the risk involved, also consent was taken from the patient. The patient was kept nil orally. The patient was shifted to OT and all standard anesthesia protocols were followed. I.V line was put in anticipation of any reaction to the local anesthetic agent. With all aseptic precautions under, the transverse process of the C6 vertebra was traced and then the longus colli muscle was located on ultrasound, by placing a probe across the right side of the neck at the level of the cricoid cartilage. The C6 vertebra, carotid artery, longus colli muscle and transverse processes of the C6 vertebrae were all recognized with a little caudal movement of the USG probe. Stellate ganglion was discovered using a linear 13-5 MHz ultrasound probe under the direction of Hitachi. With a line approach, the block was executed. A 22G 112-inch hypodermic needle connected to a 10-cm extension line was then placed at the target location under USG guidance following a local anesthetic injection of 20 ml of 2% lignocaine with preservative and inj Methylprednisolone.

After 5 minutes patient shows Horner's syndrome which included redness of eye, right-side lacrimation and pupillary dilation. This validated the validity of the block, patient had spontaneous pain relief though he had mild numbness, which persisted for duration of 1.5 hours. Patient was reviewed on basis of numeric rating scale (NRS) with 0 being no pain and 10 being severe pain, after few hours' patient had recurrence of pain as the effect of Local Anesthetic agent weaned off, the (NRS 8/10) which got settled

down gradually. Score on pain detect tool was 5, on day 15 (NRS1/10), day 30(NRS1/10) at 3months (NRS 1/10) and at 6months (NRS2/10). As a result, effective and long-lasting pain relief is provided.

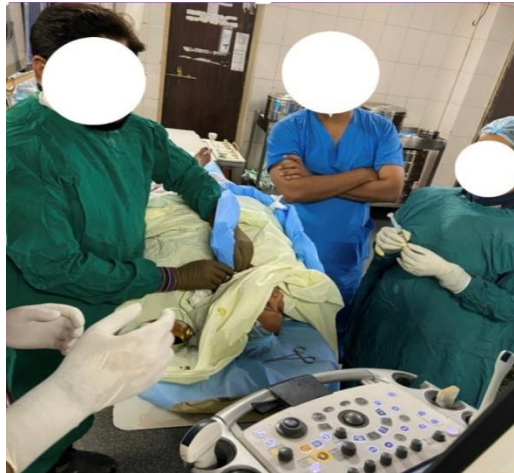

Figure 1 USG guided stellate ganglion block.

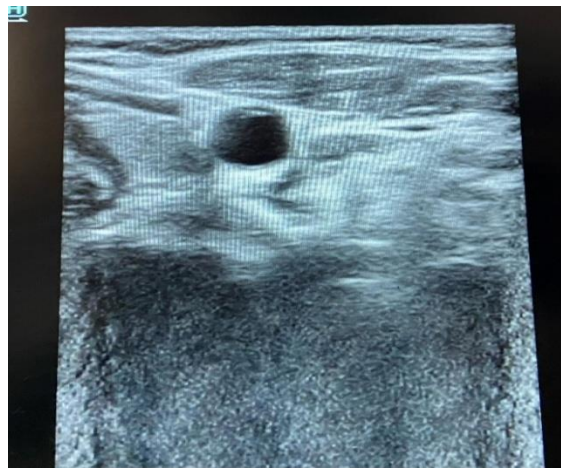


Figure 2 USG image

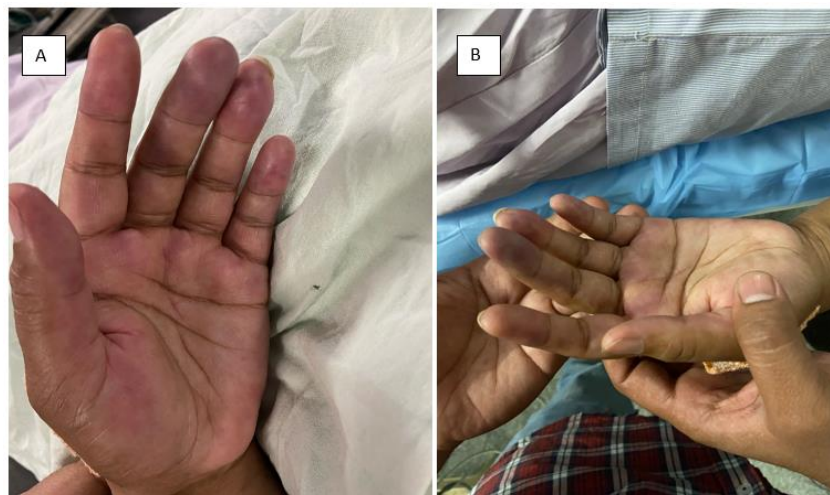

Figure 3 (A) Changes due to limb ischemia before and (B) Showing changes post ganglion is block changes

3. DISCUSSION

The subclavian artery stenosis depending upon its degree of blockage can present difficulty to the patient leading to stressful conditions both mentally as well as physically, hampering their day-to-day life. The treatment goal in such patients of Subclavian artery stenosis leading to pain and ischemia is to relieve pain and restore the inadequate arterial circulation brought on by either sympathetically induced vasospasm or vascular blockage. The treatment of peripheral vascular disease offers multiple modalities including but not limited to the open surgical approach, endogenous approach and hybrid approach. The patient tried conservative management with non-steroidal analgesia like Tab Diclofenac, agents which provided only a short-term partial relief to the patient. Thus patient was given the option of stellate ganglion block which was of short duration and minimally invasive with the help of ultrasound guidance making the procedure safer for the patient by localizing the exact site of injection along with reducing the spillage of the drug to the surrounding area and hence avoiding complications (Nishikii et al., 2019).

It is appealing to patients as well as interventionists because of its less invasive nature, shorter hospital stay and decreased postoperative complication rates. The patient immediately had relief in the symptoms with minor pre-explained side effects. The procedure was effective in making the patient free from symptoms and also helped the patient to get off medical treatment which was associated with numerous other side effects like gastritis and furthermore long-term side effects on chronic use. The procedure has known side effects like injury to the esophagus, injury to the Recurrent Laryngeal nerve leading to hoarseness of voice, deposition of the drug into any neighboring vessel and hematoma, a rare complication including damage to the phrenic nerve, all of which can be avoided with the use of USG and if done by experienced Anaesthesiologist (Elias, 2000).

The SGB was taken into account in this case because there was acute discomfort, a restriction in mobility and impending ischemia damage to the left hand that, if not treated right away, would have worsened. Block was carried out under ultrasound supervision with the required safety measures, thorough planning and monitoring. A senior, skilled anesthesiologist conducted the block while being closely watched in the operating room and 20% lipid and all other resuscitative supplies were available in case of emergency. The correct USG-guided single-shot SGB fully eliminated the symptoms. When doing a USG-guided nerve block, far less medication is administered than when performing a landmark block, as was done in the case of the current patient (Elias, 2000).

4. CONCLUSION

To summarise, Stellate ganglion block under strict supervision with the help of ultrasound guidance is a novel and helpful technique for patients suffering from Subclavian artery stenosis and finger vasculitis to relieve them from pain, enhance recovery, and minimize limb ischemia harm. It needs to be made available as a crucial element of their general administration.

Informed consent

Written and oral informed consent was obtained from the patient included in the study.

Funding

This study has not received any external funding.

Conflict of interest

The authors declare that there is no conflict of interests.

Data and materials availability

All data sets collected during this study are available upon reasonable request from the corresponding author.

REFERENCES AND NOTES

1. Bando K, Satoh K, Satoh Y, Hanaoka M, Kurashiki Y, Matsuzaki K, Miyake H, Niki H. [A Case Report of Basilar Artery Thromboembolism from Severe Stenosis of the Vertebral Artery Ostium]. *No Shinkei Geka* 2019; 47:85–90. doi: 10.11477/mf.1436203900
2. Caesar-Peterson S, Bishop MA, Qaja E. Subclavian Artery Stenosis, *Stat Pearls*. Stat Pearls Publishing 2022.
3. Elias M. Cervical sympathetic and stellate ganglion blocks. *Pain Physician* 2000; 3:294–304.
4. Kim MK, Yi MS, Park PG, Kang H, Lee JS, Shin HY. Effect of Stellate Ganglion Block on the Regional Hemodynamics of the Upper Extremity: A Randomized Controlled Trial. *Anesth Analg* 2018; 126:1705–1711. doi: 10.1213/ANE.0000000002528

5. Martínez Moreno R, Bhogal P, Lenz-Habijan T, Bannewitz C, Siddiqui A, Lylyk P, Hannes R, Monstadt H, Henkes H. In vivo canine study of three different coatings applied to p64 flow-diverter stents: Initial biocompatibility study. *Eur Radiol Exp* 2019; 3:3. doi: 10.1186/s41747-018-0084-z
6. Nishikii H, Kurita N, Kusakabe M, Yokoyama Y, Kato T, Sakata-Yanagimoto M, Obara N, Hasegawa Y, Chiba S. [Successful management of primary immune thrombocytopenia with romiplostim during open heart surgery in a hemodialysis patient]. *Rinsho Ketsueki* 2019; 60:28–32. doi: 10.11406/rinketsu.60.28