

Fatal HELLP syndrome in pregnancy: A sequelae of Long COVID?

Ojas Mahajan¹, Dhruv Talwar^{1✉}, Sunil Kumar², Arpita Jaiswal³, Sparsh Madaan⁴, Shivam Khanna¹, Divit Shah¹

To Cite:

Mahajan O, Talwar D, Kumar S, Jaiswal A, Madaan S, Khanna S, Shah D. Fatal HELLP syndrome in pregnancy: A sequelae of Long COVID?. Medical Science, 2021, 25(114), 1878-1881

Author Affiliation:

¹Post Graduate Resident, Department of Medicine, Jawaharlal Nehru Medical College, Datta Meghe Institute of Medical Sciences and Research (Deemed to be university), Maharashtra, India

²Professor, Department of Medicine, Jawaharlal Nehru Medical College, Datta Meghe Institute of Medical Sciences and Research (Deemed to be university), Maharashtra, India

³Professor, Department of Obstetrics and Gynaecology, Jawaharlal Nehru Medical College, Datta Meghe Institute of Medical Sciences and Research (Deemed to be university), Maharashtra, India

⁴Post Graduate Resident, Department of Obstetrics and Gynaecology, Jawaharlal Nehru Medical College, Datta Meghe Institute of Medical Sciences and Research (Deemed to be university), Maharashtra, India

✉Corresponding author

Post Graduate Resident, Department of Medicine, Jawaharlal Nehru Medical College, Datta Meghe Institute of Medical Sciences and Research (Deemed to be university), Maharashtra, India
Email: dhruv.talwar2395@gmail.com

Peer-Review History

Received: 19 June 2021

Reviewed & Revised: 21/June/2021 to 22/July/2021

Accepted: 23 July 2021

Published: August 2021

Peer-review Method

External peer-review was done through double-blind method.

ABSTRACT

The coronavirus disease resulted by infection with severe acute respiratory syndrome-Coronavirus 2 (SARS-CoV-2) was initiated in China in during the end of 2019 and spread exponentially as a global health Pandemic. The current pandemic (COVID-19) caused by SARS-CoV-2 novel coronavirus lead to high mortality and morbidity in terminally ill patients. We present a link between maternal severe acute respiratory syndrome-Coronavirus 2 (SARS-CoV-2) infections in the peripartum period and rapid maternal deterioration with coagulopathy. Also, we wish to draw attention towards the overlap which is significant between the clinical findings of COVID19 and HELLP Syndrome along with importance of persistence of inflammation over 3 months after COVID19 known as “Long COVID”.

Keywords: Pregnancy, HELLP Syndrome, COVID -19

1. INTRODUCTION

The novel coronavirus outbreak occurred in December of 2019 in the form of pneumonia cases in Wuhan, China. It spread exponentially and WHO declared it as a pandemic on 11th March 2020 (Talwar et al., 2021). While its effects on respiratory symptoms are well recognized, gynecological manifestations have been rarer. In pregnancy, physiological changes like increased oxygen intake, respiratory tract edema and immunity function leads to increased complications during pregnancy. Blood investigations could mimic HELLP Syndrome. There is noteworthy overlap of COVID19 with HELLP Syndrome which is a known severe syndrome associated with pregnancy. HELLP is diagnosed by diagnostic criteria which includes three important aspects of microangiopathic hemolysis with schistocytes seen on peripheral blood smear, raised liver enzymes along with thrombocytopenia. HELLP generally presents with hypertension along with excessive protein excretion in urine thus representing pre-eclampsia in its severe form, some atypical manifestations are also reported. Some complications which are usually witnessed in COVID19 include Disseminated Intravascular Coagulation (DIC) including elevation of D-Dimer along with microangiopathic hemolytic anemia. Certain studies show pregnant patients with COVID19 to have elevated C reactive protein along with elevated liver



enzymes and lymphopenia. LONG COVID is a term describing long term inflammation of more than 3 months in case of COVID19 patient. It is a long-term progression of post COVID sequelae. While association and overlap of COVID19 with HELLP syndrome is well documented this is the first case report showcasing HELLP Syndrome as a sequelae of Long Covid. We describe a case of 23 years old female with history of COVID19 5 month's back, ANC Para 1 Death 1 Abortion 2 who presented with HELLP syndrome.

2. CASE REPORT

A 23 years old female patient Para 1 Death 1 Abortions 2 a case of day 5 post emergency LSCS came to the casualty with history of breathlessness even at rest and palpitations since 3 days. Patient was a known case of PreEclampsia with HELLP syndrome and Diabetes Mellitus type 1 since 3 years and was on Beta Blocker and Insulin for the same. Patient had history of COVID-19 during the first month of pregnancy. She was managed with IV antibiotics and discharged uneventfully. On general examination, patient was afebrile with a pulse of 110 per minute, regular in rhythm, blood pressure of 110/70 mmhg in right arm supine position. Cyanosis and clubbing was present. On Systemic examination, patient was drowsy and irritant, Bilateral plantar was flexor. Bilateral crepts were present, normal heart sounds were heard and on abdominal examination uterus were 21 weeks in size, relaxed, cephalic, fetal heart sounds was present/regular/154bpm. Her laboratory investigations showed increased inflammatory markers with a picture of HELLP Syndrome (Table 1). Her Obstetric USG revealed Single live intrauterine fetus of 21 weeks 4 days maturity in variable presentation with borderline oligohydramnios and grade 2 placenta previa.No obvious detectable structural anomalies was seen. A shielded chest x ray revealed consolidation (Figure 1). Patient was treated with Antibiotics along with low molecular weight heparinand steroids. Patient's oxygen saturation deteriorated subsequently in view of which the patient was put on non invasive ventilation with Oxygen support. During further course of hospital stay, on the 2nd day of admission the patient was intubated and taken on mechanical ventilator. During the course of Hospital stay patient deteriorated further and succumbed on 4th day post admission.

Table 1 showing lab investigations of the case

CBC	Hb-9.2 gm/dl MCHC- 27.6 MVC- 77.5 MCH- 21.4 Red Blood Counts- 5.24 millions per cubic mm HCT- 40.6 Monocytes- 6 Granulocytes-82 Lymphocytes- 10 RDW- 16.8 Eosinophils- 02 Basophils- 00 White Blood Counts- 30,700 per cubic mm Platelets- 90000 per cubic mm N/L Ratio = 8.2
KFT	Urea- 47 Serum Creatinine-1.1 Serum Sodium-141 meq/l Serum Potassium- 3.9 meq/l
LFT	Alkaline Phosphatase- 119 Aspartate aminotransferase-546 Alanine Transaminase-287 Total bilirubin-5.4 Unconjugated-4.4 Conjugated-1.0 Total protein -5.0gm/dl Albumin-2.0gm/dl Globulin-3.0gm/dl
D-dimer	7.94
LDH	2051

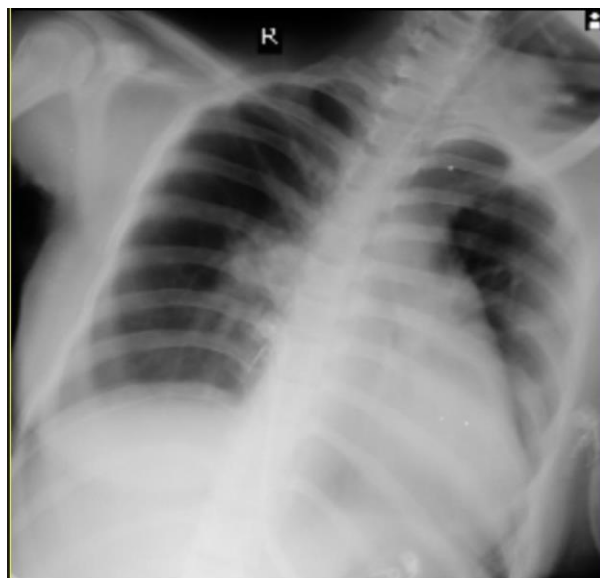


Figure 1 Chest X Ray PA view of this patient

3. DISCUSSION

HELLP is diagnosed by a criterion involving three domains of elevated liver enzymes, microangiopathic hemolysis with schistocytes on peripheral blood smear and thrombocytopenia. Atypical representations have been quoted in literature apart from typical presentations of hypertension and proteinuria representing a severe form of preeclampsia. Leukopenia or lymphopenia along with elevated liver enzymes are some of the common abnormalities seen in COVID-19 patients. Coagulation and fibrinolytic pathways are both triggered simultaneously here, possibly due to sepsis, resulting in the consumption of clotting-related factors. Clinical presentation of this coagulopathy can vary from thrombotic to hemorrhagic. In Pregnancy, there is physiological increase in coagulation due to rise in factors of coagulation along with fibrinogen and D-dimer to about 50% above the normal value by the last trimester which further complicates this hypercoagulable state (Lillicrap, 2020). A weak prognostic predictor of COVID-19 is an increase in platelet count, a decrease in fibrinogen, and an increase in D-dimer. In pregnancy, the only coagulation criteria associated with the severity of postpartum hemorrhage were decreased fibrinogen levels. Lymphocytes have an important role in assessing the response of the immune system in COVID-19 as reduction in lymphocyte count is associated with severity of illness and hospital admission.

In a study conducted in Wuhan [China], over 85 percent of the patients encountered lymphopenia. Transaminitis has been frequently found in SARS and MERS-CoV infected patients. We show a probable relation with sudden maternal deterioration between the last trimesters of maternal COVID-19 infection and increasing coagulopathy that improved after delivery (Boettler et al., 2020). The laboratory results of our case mentioned may be suggestive of HELLP syndrome and therefore understanding of the relationship between COVID-19 and coagulopathy and, in turn, HELLP syndrome is of great importance to correct diagnosis and prompt intervention to predict and prevent maternal mortality (Huang et al., 2020). HELLP complicates 0.5 to 1 percent of pregnancies and with serious preeclampsia can be seen with 20 percent of HELLP. AKI is often correlated with HELLP, making 7 to 15 percent of cases complicated. HELLP is commonly believed to be a serious type of preeclampsia, although there are no documented symptoms or any signs suggestive of preeclampsia in up to 15 to 20 percent of patients. HELLP Syndrome can be progressive leading to rapid deterioration. HELLP's pathophysiology is not clearly understood however there are various theories that attempt to identify the trigger for this disease. Damage to the Endothelium as a result of activation of platelet resulting in platelet aggregation, is present in the pathophysiological phase of HELLP similar to COVID-19 (Jain et al., 2020).

HELLP can also be correlated with DIC, and some researchers assume that the primary mechanism is DIC; Two Third of HELLP Cases present in the third trimester, while one third of the cases manifest within two days of postpartum; delivery is known as first-line care. In order to prevent progression to eclampsia, additional use of magnesium sulphate is advised, as is the management of hypertension with antihypertensives (Kline et al., 2005). A large amount of analysis is currently under review into COVID-19 and its harmful manifestations on pregnant patients along with their fetus who are yet to be born. In the general population, there are already records of deranged enzymes of liver, reduced platelet count, coagulopathy including DIC, cardiomyopathy, acute kidney injury and Acute Respiratory Distress Syndrome. Patients who are pregnant generally present with signs and symptoms which are similar with many of the abnormalities in the lab investigations like the rest of COVID-19 patients (Dashrath et al., 2019).

Research regarding the immediate and long term maternal and fetal consequences remains limited and is a topic of further research. Thus whenever there is a differential of HELLP syndrome documentation of a respiratory process might help in early diagnosis of COVID19. While HELLP Syndrome will start to settle twenty four hours to seventy two hours post delivery, the course of COVID19 is unrelated to the delivery timing (Tang et al., 2019). Our case Report supports the testing for COVID19 in pregnant women for early diagnosis. If the diagnosis is made early the physicians and obstetricians can be on lookout for complications even after COVID19 is treated thus indicating LONG COVID19 has a long term association of inflammation going on for months after COVID19. This long term inflammation might have precipitated HELLP Syndrome in this patient.

5. CONCLUSION

To conclude the team of obstetricians and physicians should be on lookout for the dangerous overlap of COVID19 with HELLP Syndrome and Diagnosis of COVID anytime during the Pregnancy should be warranting of future complication of Long COVID resulting in HELLP Syndrome. Timely diagnosis and vigilance in regard to Long Covid can thus prevent mortality.

Acknowledgement

We thank all the participants who have contributed in this Study.

Conflict of interest

The Authors have no conflicts of interest that are directly relevant to the content of this clinic-pathological case

Financial Resources

There are no financial resources to fund this study

Informed Consent

Informed Consent was obtained from the patient.

Author's Contribution

All the authors contributed equally to the case report.

Data and materials availability

All data associated with this study are present in the paper.

REFERENCES AND NOTES

- Boettler T, Newsome PN, Mondelli MU. Care of patients with liver disease during the COVID-19 pandemic: EASL-ESCMID position paper. *JHEP Rep* 2020;2(03):100113
- Dashrath P, Jing Lin Jeslyn W, Mei Xian Karen L. Coronavirus Disease 2019 (COVID-19) pandemic and pregnancy. *Am J Obstet Gynecol* 2019; 222:521-531
- Huang C, Wang Y, Li X. Clinical features of patients infected with 2019 novel coronavirus in Wuhan, China. *Lancet* 2020; 395 (10223):497–506
- Jain A, Talwar D, Kumar S. Spectrum of Respiratory Involvement in COVID 19 Era; an Overview. *Indian Jof Forensic Med & Toxicol* 2020; 14(4):6593-9.
- Kline JA, Williams GW, Hernandez-Nino J. D-dimer concentrations in normal pregnancy: new diagnostic thresholds are needed. *Clin Chem* 2005; 51(05):825–829
- Lillicrap D. Disseminated intravascular coagulation in patients with 2019-nCoV pneumonia. *J Thromb Haemost* 2020;18(04):786–787
- Talwar D, Kumar S, Madaan S, Khanna S, Annadatha A. Intractable Singultus: Atypical presentation of COVID 19. *Medical Science* 2021; 25(111), 1183-1187
- Tang N, Li D, Wang X, Sun Z. Abnormal coagulation parameters are associated with poor prognosis in patients with novel coronavirus pneumonia. *J Thromb Haemost* 2020; 18:844-847.