

Acute suicidal psychotic illness in mentally healthy patient: Is it COVID-19?

Dhruv Talwar¹, Sunil Kumar^{2✉}, Sourya Acharya³, Saniya Khan¹, Prerna Verma¹

To Cite:

Talwar D, Kumar S, Acharya S, Khan S, Verma P. Acute suicidal psychotic illness in mentally healthy patient: Is it COVID-19?. *Medical Science*, 2021, 25(112), 1277-1280

Author Affiliation:

¹Post Graduate Resident, Department of Medicine, Jawaharlal Nehru medical college, Datta Meghe Institute of Medical Sciences (Deemed to be University), Wardha, Maharashtra, India

²Professor, Department of Medicine, Jawaharlal Nehru medical college, Datta Meghe Institute of Medical Sciences (Deemed to be University), Wardha, Maharashtra, India

³Professor and Head of Department, Department of Medicine, Jawaharlal Nehru medical college, Datta Meghe Institute of Medical Sciences (Deemed to be University), Wardha, Maharashtra, India

✉Corresponding author

Professor, Department of Medicine, Jawaharlal Nehru medical college, Datta Meghe Institute of Medical Sciences (Deemed to be University), Wardha, Maharashtra, India
Email: sunilkumarmed@gmail.com

Peer-Review History

Received: 07 April 2021

Reviewed & Revised: 09/April/2021 to 21/May/2021

Accepted: 22 May 2021

Published: June 2021

Peer-review Method

External peer-review was done through double-blind method.

ABSTRACT

A 46 year old male previously healthy with no personal or family history of mental illness reported with a new onset psychosis after he was diagnosed with a symptomatic COVID-19 infection. His psychotic symptoms subsided substantially with antipsychotics along with benzodiazepines and improved further with resolution of his other COVID-19 symptoms. This case report showcases the importance of vigilance and monitoring of COVID-19 patients for development of neuropsychiatric symptoms leading to prompt diagnosis and management.

Keywords: COVID-19, Psychosis, mental illness

1. INTRODUCTION

The Novel Coronavirus (severe acute respiratory coronavirus 2) is the causative virus of COVID-19 infection which has led to a deadly pandemic crippling the world's healthcare services. The first case of COVID-19 was recorded in Wuhan, China. Since then it has spread across the world causing a phenomenal rise in morbidity and mortality (Mao et al., 2020). There is a wide variety of presentations of COVID-19 which has led to great difficulty in diagnosis and managing the patients. The presentations can range from a totally asymptomatic patient to Mild Respiratory Symptoms to devastating Respiratory Failure.

COVID-19 infection has typical symptoms of breathlessness, cough, fever and myalgia along with sore throat. It has also been reported to effect the central nervous system leading to cerebrovascular episode, encephalitis, encephalopathy as well as aguesia and anosmia. There has been prior reporting of cases with SARS including anxiety, suicidal ideation, depression, hallucinations and organic manic disorder (Sheng et al., 2005). In the Past, patient who has recovered from SARS-COV1 have reported to suffer from post traumatic stress disorder, panic disorder, depression and obsessive compulsive disorder. There has been a recent reporting of reactive psychosis due to COVID-19 infection but not much importance has been given to this incident psychosis presenting with COVID.

Most of the patients developing COVID-19 induced psychosis have had past or family history of COVID-19 (Arbour et al., 2000).



DISCOVERY
SCIENTIFIC SOCIETY

© 2021 Discovery Scientific Society. This work is licensed under a Creative Commons Attribution 4.0 International License.

Here we present a case of Middle aged male who developed Psychosis due to COVID-19 but had no prior family or personal history of Psychosis or any other psychiatric illness.

2. CASE REPORT

A 46 year old male with no psychiatric history presented to the outpatient department with symptoms of rhinorrhoea and nasal congestion since 3 day following a exposure to COVID-19 at his locality 7 days back. Two days after he developed symptoms involving upper respiratory tract the patient was found to develop a sudden onset rapidly progressive change in his behaviour which was indicated by prominent persecutory delusions along with insomnia. His Dellusions were directed towards his safety and his finances.

He believed to have a threat to his life and that someone was going to try to steal his wealth. Further information from his family revealed that he was having ruminative and persecutory thought patterns involving him to be attacked and his cell phone to be tracked by someone. He was diagnosed as a COVID-19 positive case following a nasopharyngeal swab by reverse transcription polymerase chain reaction method and was admitted.

On examination the patient was afebrile with pulse of 88 beats per minute, regular in rhythm; blood pressure was 130/80 mm hg in right arm in supine position. On systemic examination patient had Bronchial Breath sound in bilateral inframammary areas, Hear sounds were normal, Abdomen was soft non tender and there was no organomegaly. On Central Nervous Examination patient was avoiding eye contact but had no psychomotor agitation or retardation. The rate of his speech was found to be increased though it was interruptible with repeated prompts. His thought process was found to be tangential with persecutory delusions. He also revealed to have suicidal thoughts.

Patient denied having any homicidal thoughts. His attentions, concentration along with orientation were found to be intact. There was no neck rigidity or other signs of meningitis. Fundus examination showed no signs of papilledema. His HRCT Chest was done which revealed multolpleill defined patchy ground glass opacities with septal thickening in bilateral lung fields (CT Severity Score 9/25,CORAD 6) (Figure 1). MRI Brain was done and it showed no obvious abnormality (Figure 2). Laboratory Investigations are mentioned in Table 1. Cerebrospinal Fluid analysis showed CSF to be colourless, Glucose-66mg.dl, Protein 24mg/dl, WBC count-4 cells (all mononuclear) with no red blood cells. Cerebrospinal Fluid analysis for extended Polymerase Chain Reaction Panel for Meningitis was also sent which turned out to be negative. Due to the shortage of alternative diagnosis for his development of this acute psychosis it was thought that the presentation of his psychosis was either a symbol of a first episode psychosis which got triggered due to the psychological and social stressors that were due to his COVID infection or just a brief psychotic disorder in the background of a obvious stressor or a rare immediate sequelae to COVID-19 and a symbol of a brief psychiatric disorder.

An alternate diagnosis of delirium was also thought of but it was excluded as the patient did not have any deficiencies in attention nor in awareness during his examination. He was initially treated with olanzapine targeting his psychiatric symptoms along with help sedation to restore his disrupted sleep cycle. Despite the initiation of olanzapine patient continued to be in paranoia and thus clonazepam was added to his prescription for acute anxiety started as a twice daily dose and later titrated to a single dose daily. He was also started on Remdesavir, antibiotics, Low moledcular Weight heparin and other supportive measures. During the course of hospital stay patient improved clinically, was stabilised followed by discharged on oral risperidone and is doing well on follow up.

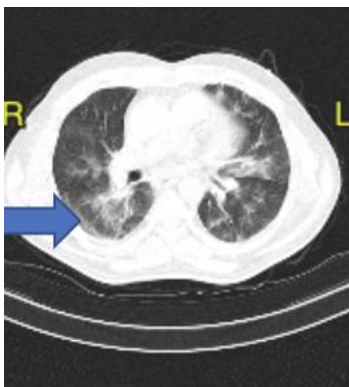


Figure 1 Showing Ground Glass Opacity on HRCT Chest

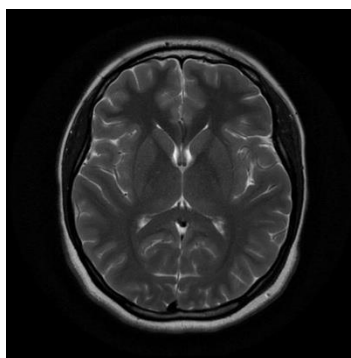


Figure 2 MRI Brain Showing No Obvious Abnormality

Table 1 Showing lab investigations of the Case

CBC	Hb-11.8gm/dl, MCV-82fl, Platelet count-99000/dl WBC Count-5600/dl
LFT	Total Protein-6.1gm/dl, Albumin3.4gm/dl, Globulin2.7gm/dl, aspartate aminotransferase 21 units/l , alanineaminotransferase 29 units/l, AlkanlinePhophatase 114 IU/l, Total Bilirubin :0.9mg/
KFT	Creatinine:0.7mg/dl, Urea28mg/dl, Sodium136mmol/l, Potassium -3.9mmol/l
CRP	72.0mg/dl
D-Dimer	1.3
Serum Ferritin	880ng/ml

3. DISCUSSION

Symptomatic COVID-19 leading to psychosis is a rare entity in a patient with no past or family history of psychosis or any other psychiatric illness. In our case there was no history of any prodromal symptoms and there was a brief episode of psychosis which resolved with treatment. Also, our patient did not have history of any substance abuse or use of any psychotic drugs (eg-steroids). The onset of psychosis was also related to respiratory symptoms involving the upper respiratory tract. Due to the temporal relationship between the onset of respiratory symptoms and psychosis and resolution of psychosis following improvement of respiratory systems a provisional diagnosis of COVID-19 associated brief psychosis was made. The pathophysiology of the psychosis may be related to the uncontrolled stress which is associated with the ongoing pandemic in the patients who are vulnerable psychologically. However the increased inflammation shown by elevated inflammatory markers in our patient makes virus associated inflammation trigger a probable etiology. Delirium must also be kept as an alternative diagnosis in such patients.

The patient had acute onset psychosis but was oriented fully but disorganised. The Cytokine Storm seen in COVID-19 may also be an etiological factor for psychiatric symptoms which was earlier only linked to fatal pulmonary and cardiac complications. It is postulated that coronavirus affecting the humans may perform as an opportunistic pathogen for central nervous system as they have been proved to have properties which are neuroinvasive in nature due to autoimmunity and replication of virus (Jain et al., 2021). This penetration and neuroinflammation may be the cause of the acute onset new psychotic disorders as well as Central Nervous system infections (Troyer et al., 2020). A complete and thorough work up should be done for a patient presenting with a first episode of psychosis.

In our case we have performed imaging as well as lumbar puncture along with other relevant lab investigations to investigate this first psychotic episode in our patient. While treating a patient of COVID-19 with psychosis we follow the protocol of

management of secondary psychosis with emphasis on treating the underlying COVID infection while managing the psychosis with antipsychotic medications and benzodiazepines. The dose of antipsychotics and benzodiazepines should be titrated to lowest possible dose. In our case the patient responded well to combination of olanzapine plus clonazepam and patient was discharged on risperidone. In patients not compliant to therapy syrup risperidone can be mixed along with food and given.

Haloperidol should be avoided in patients who have a co-existing cardiac disease due to risk of dysrhythmias in such patients (Wilson et al., 2012). A follow up for such patients in the outpatient department is crucial to look for any recurrences of such episodes in the future. We also lay out through this case report the lack of studies on COVID-19 induces psychosis and research on its management making its management difficult. The early diagnosis and management of such a psychosis in a COVID-19 patient is extremely crucial and can prove to be life saving for the patient.

4. CONCLUSION

Through this case report we would like to emphasise on the fact that the patients infected with COVID-19 have a risk of developing neuropsychiatric manifestations which includes psychosis. Thus, Physicians treating COVID-19 patients should be on a lookout of Psychosis especially in patients who are vulnerable as they may be predisposed to psychosis by COVID. The diagnosis of this COVID-19 induced psychosis should be a prompt one and should include a complete physical and psychiatric examination. Hence we conclude that in locations endemic for COVID-19 for a patient presenting new onset psychosis we should be considerate for testing of COVID-19 even in the absence of respiratory symptoms.

Acknowledgement

We thank all the participants who have contributed in this Study.

Conflict of interest

The Authors have no conflicts of interest that are directly relevant to the content of this clinic-pathological case

Financial Resources

There are no financial resources to fund this study

Informed Consent

Informed Consent was obtained from the patient.

Author's Contribution

All the authors contributed equally to the case report.

Data and materials availability

All data associated with this study are present in the paper.

REFERENCES AND NOTES

1. Arbour N, Day R, Newcombe J. Neuroinvasion by human respiratory coronaviruses. *J Virol* 2000; 74:8913–21.
2. Jain A, Talwar D, Kumar S. Spectrum of Respiratory Involvement in COVID-19; An Overview. *Ind J of Forensic Med & Toxicol* 2021; 14(4), 6593-99.
3. Mao L, Jin H, Wang M. Neurologic manifestations of hospitalized patients with coronavirus disease 2019 in Wuhan, China. *JAMA Neurol* 2020; 77:1–9.
4. Sheng B, Cheng SKW, Lau KK. The effects of disease severity use of corticosteroids and social factors on neuropsychiatric complaints in severe acute respiratory syndrome (SARS) patients at acute and convalescent phases. *Euro Psy* 2005; 20:236–42.
5. Troyer EA, Kohn JN, Hong S. Are we facing a crashing wave of neuropsychiatric sequelae of COVID-19? Neuropsychiatric symptoms and potential immunologic mechanisms. *Brain, Behaviour and Imm* 2020; 87:34–9.
6. Wilson MP, Pepper D, Currier GW. The psychopharmacology of agitation: consensus statement of the American association for emergency psychiatry project beta psychopharmacology Workgroup. *West J of Emerg Med* 2012; 13:26–34.