

To Cite:

Mohamed MO, Adam EA, Abdlla BM, Abdelghani S, Eltayeb LB. Vascular Endothelial Growth Factor (VEGF) as biological markers expressed in ovarian cancer using immuno-histochemical technique. *Medical Science*, 2021, 25(112), 1311-1317

Author Affiliation:

¹Department of Histopathology and cytology, Faculty of Medical Laboratory Sciences, Al- Neelain University, Khartoum, Sudan

²Department of clinical chemistry, Faculty of Medical Laboratory Sciences, Al Neelain University, Khartoum, Sudan

³Department of parasitology, Faculty of Medical Laboratory Sciences, Al-Neelain University, Khartoum, Sudan

⁴Department of Medical Laboratory Sciences, College of Applied medical sciences, Prince Sattam Bin Abdul-Aziz University, Al-Kharj, Riyadh, KSA

Corresponding author

Department of Medical Laboratory Sciences, College of Applied medical sciences, Prince Sattam Bin Abdul-Aziz University, Al-Kharj, Riyadh, KSA

Email: lindarose009@hotmail.com

Peer-Review History

Received: 18 April 2021

Reviewed & Revised: 20/April/2021 to 27/May/2021

Accepted: 28 May 2021

Published: June 2021

Peer-review Method

External peer-review was done through double-blind method.

Vascular Endothelial Growth Factor (VEGF) as biological markers expressed in ovarian cancer using immuno-histochemical technique

Misaa Omer Mohamed¹, Elsadig Ahmed Adam¹, Banaga Mnsoor Abdlla², Sara Abdelghani³, Lienda Bashier Eltayeb⁴✉

ABSTRACT

Background: Vascular endothelial growth factor (VEGF) has vital role in tumor metastasis through triggering the accumulation of abnormal blood vessels. **Aim:** The study aimed to evaluate the expression of VEGF in ovarian cancer in Sudanese patients to assess the correlation between expression of this marker and patient's age. **Methods:** A vascular endothelial growth factor expression was detected by immune-histochemical method on total of 38 Paraffin blocks of which 24 cases previously diagnosed as serous carcinoma and 14 cases mucinous carcinoma using routine Hematoxylin and Eosin stain. **Result:** Using 38 (FFPE) block of ovarian tumor; histopathological diagnosis of samples revealed that 14(37%) of samples were mucinous, 24(63%) samples were serous carcinoma. Patients ages ranged between 26-70 years, majority of them (42.1%) were in age group 47-58 years old. The VEGF marker were expressed in 29 ovarian paraffin wax embedded blocks, 19(50%) positive in SOC, while MOC 10(26.3 %) were positive the result statistically insignificant (P-value 0.855). 9(23.76%) were positive in age group (26-36), and 12(31.5%) were positive in age group (48-58) the result statistically significant p-value (0.044). **Conclusion:** There is statistically significant association between VEGF expression and advance age, while didn't correlated with histological types of ovarian cancer. Further study should be done involving large sample size of ovarian cancer using more advance technique such as ovarian cancer Vm RNA testing.

Keywords: Ovarian cancer, VEGF, Immuno-histochemical stain

1. INTRODUCTION

Ovarian cancer is a type of euangiogenic tumor, which has numerous pathological types and no rational clinical symptoms. Ovarian cancer is indeed



© 2021 Discovery Scientific Society. This work is licensed under a Creative Commons Attribution 4.0 International License.

very malignant and has a poor prognosis. It is hard to ascertain early, but it may display enormous peritoneal metastases (Parkin et al., 2004). Ovarian cancer is the most frequent cancer among female presently, and frequently diagnosed cause of cancer death, as well as the second most frequently diagnosed malignancy in female population. In 2002, the approximate number of new cases of ovarian cancer globally has been more than 204,000, with 125,000 fatalities (Parkin et al., 2005; Henderson et al., 2018). Despite significant advances in the treatment of ovarian cancer, it is almost deadly female reproductive system tumor caused by of scarcity of early indications of danger and ideal screening techniques (Roett et al., 2009). The danger of ovarian cancer rises in females who have ovulated much during their entire life. This involves those who have never had children, others who started ovulation at a relatively young age, or who reach menopause at an advanced age. Other risk factors are including menopausal hormonal treatment, fertility medicines, and obesity. Characteristics that minimize the risk include hormonal birth control, tubal ligation and breast feeding (Jacobs et al., 2004). Approximately 10% of cases are triggered by inherited genetic risk; females who have mutations in the genes BRCA1 or BRCA2 have a 50% higher risk of disease. There is presently hardly an excellent screening test for ovarian cancer, and almost two thirds of cancers really are not diagnosed after they have spread further than pelvis. Consequently, survival rate for ovarian cancer is only about 45% (Henderson et al., 2018). As a result, by the time cancer is diagnosed, it has indeed progressed to an advanced stage. About 95% of the ovary tumors are epithelial, which started in superficial coat of the ovary. Serous, Endometriosis, Clear cell, Mucinous and Undifferentiated or unclassifiable are distinct sorts of epithelial carcinomas infect ovary (Roett et al., 2009 and Jacobs et al., 2004).

Serous epithelial ovarian cancer is the ultimate widespread form, which account around two thirds of the cases diagnosed. These early cancer cells afterward diffused and develop in the ovary. Undifferentiated or unclassifiable epithelial ovarian cancer accounts for about 10% of all cases (Roett et al., 2009). Several studies have importantly been developed to enhance the diagnostic accuracy of ovarian cancer, including monitoring investigation tests for initial stage tumors just using imaging modalities and tumor markers. Plenteous molecular agents from samples collected from clinically diagnosed cervical cancer patients have also shown capability as serological biomarkers, moreover, only small minority have been used in clinical studies and screening assessments (Jacobs et al., 2004; Robati et al., 2013). Vascular endothelial growth factor (VEGF), also widely recognized as vascular permeability factor, is indeed a dimeric protein found in bovine pituitary folliculostellate cells (Choi et al., 2008). VEGF isoforms 121, 165, 189, and 206 vary greatly in molecular weight and biological behavior and are transcribed from a single gene on human chromosome 6 as a consequence of point mutation (Kaya et al., 2004).

VEGFs are generated by regular cell types such as smooth muscle, corpus leuteum, and adrenal cortex cells and maintain their effect by attaching to a family of VEGF receptors known as Flt, Flt1/KDR, and Flt4, which have been primarily expressed on endothelial cells. This suggests that only the endothelial cells are assigned to carry the mitogenic VEGF signals to the cell nuclei. It is now known that many human tumors, like breast and colon, over express VEGF (Kumaran et al., 2009 and Bull Phelps et al., 2008), and this enhances tumor angiogenesis, by autocrine and paracrine mechanisms. Some researchers have postulated that the expression of VEGF receptors in tumor cells (accumulated throughout neoplastic transformation) promotes autocrine VEGF action on them (Tanaka et al., 2011). By this mechanism, it is thought that VEGFs carry out their mitogenic activity in the tumor cells thereby enhancing tumor proliferation. In ovarian carcinomas, VEGF has an additional role, causing tumor associated ascitis as a result of its power to enhance vascular permeability (Ravikumar et al., 2013 and Frumovitz et al., 2010). Ovarian cancer is common cancer and there are many pathways involved in development of ovarian cancer, angiogenesis has a significant role in tumor growth and metastasis, and vascular endothelial growth factor (VEGF) represents a potent cytokine in this process (Wright et al., 2009 and Vasudevan et al., 2018). The purpose of this study is to identify the pattern expression of VEGF as tumor marker in mucinous and serous carcinoma and correlate with age and stage in Sudanese women.

2. MATERIAL AND METHODS

Study design

This is a descriptive retrospective cross-sectional study; to assess the expression of VEGF in (FFPE) ovarian block previously diagnosed as serous carcinoma and mucinous carcinoma among Sudanese patient from May 2019- January 2020. Samples collected from patient's attending Military hospital and at Center of Isotope and Nuclear Medicine Khartoum (RICK) Khartoum/Sudan.

Methods

Sample size

A total of 38 Paraffin blocks of which 24 cases previously diagnosed as serous carcinoma and 14 cases mucinous carcinoma using routine Hematoxylin and Eosin stain.

Sample preparation

A paraffin blocks were collected from each section of 3µm thin were cut, sections floated into preheated floating water bath at 40°C, slides were coated with adhesive salinized glass slide for Immunohistochemistry

Immuno-histochemical Staining procedures

Procedure was carried out using mono clonal mouse anti human VEG clone MIB-1, as follows: Forty Sections (3µm) from formalin-fixed, paraffin-embedded tumors was cut and mounted onto salinized slides (thermo). Following de-paraffinization in xylene, Slides were rehydrated through a graded series of alcohol and were placed in running water. Samples steamed for antigen retrieval for VEGF using PT, slides was placed in Coplin jars containing enough sodium citrate buffer (pH 9.0), then was boiled at high Temp for 10minutes then sections were cooled at RT. Endogenous peroxidase activity has been stopped for ten min with 3% hydrogen peroxidase and methanol for 10 minutes, followed by 20 minutes at room temperature in a moisture compartment with 100-200 l of primary antibodies, followed by a wash in Phosphate buffer saline. The main VEGF antibody (monoclonal) was available for use (Thermo Kit). Then, the biotinylated link was added for 10 minutes and washed in three changes of PBS, followed by addition of 3, 3 diaminobenzidine tetra hydrochloride (DAB) as a chromogen to generate the distinctive brown stain for visual representation of the antibody/enzyme complex for up to 5 min. Haematoxylin was used to counterstain the slides. Positive and negative control slides were prepared to every staining run. The positive control slides incorporate the antigen under examination, whereas this negative control slides were made from the same tissue block and yet incubated in PBS rather than the primary antibody. Thus, every slide has been examined by a researcher, and the findings were verified by a histopathology specialist.

All histological sections showed fair staining quality and all quality control measures was considered throughout study procedures. Positive VEGF staining was identified in form of dark brown colorwhen staining was positive; it was mostly found in the cytoplasm.

Statistical analysis

The obtaining results, as well as all clinical information data were entered a computer, SPSS (version 21) program was used to analyze data, to give the frequency of cancer with age, also to show the relation of the expressed marker with serous and mucinous ovariancancer.

Ethical Clearance

The proposal was approved from histopathology and cytology department at Al-NeelainUniversity Institutional Review Board (IRB), reference NO AU/FM/EC (130) and data were taken from records inhospitals.

3. RESULTS

A total of 38 patients block samples were enrolled, their age range between (26 to 70) years old; most of them 16 (42.1%) were between the age group (47-58) years old. 24(63%) of samples were diagnosed as serous carcinoma, and 14 (37%) were mucinous carcinoma all baseline data were shown in Table (1). Table 2 summarized the expression of VEGF marker which expressed in 29 (76.3%) of samples.

The association between ovarian cancer (mucinous and serous carcinoma) and expression of VEGF marker was summarized in Table (3), 19(50%) cases positive in SOC. While MOC, 10(26.3%) cases were positive, the result statistically insignificant (P-value 0.855). An association between the age and expression of VEGF marker show in table (4). VEGF marker were never expressed in age group (26-36), while 9(23.76%) were positive in age group (37-47), 12 (31.5%) were positive in age group (48-58), the result statistically significant P-value (0.044), Pearson's R-value 0.263. Figure 1 display an immunohistochemistry showing nuclear and cytoplasmic positivity for VEGF in the neoplastic cells of ovarian Mucinous, and serous carcinoma (×400).

Table 1 Frequency of Baseline Characteristics of study population

Parameters	Frequency (n=38)	Percent (%)
Age		
26-36 years old	2	5.3%
37-47 years old	11	28.9%

48-58 years old	16	42.1%
59-70 years old	9	23.7%
Mean ±SD		
Type of ovarian cancer		
SeriousCarcinoma	24	63%
MucinousCarcinoma	14	37%
Total	38	100.0%

Table 2 Frequency of Immuno-histochemical result of VEGF

Parameters	Frequency n=38	Percent (%)
Positive VEGF	29	76.3%
Negative VEGF	9	23.7%
Total	38	100

Table 3 Relation of VEGF Immune-result with type of ovarian cancer

Types of ovarian cancer	VEGFImmuno-histochemical		Total
	Positive	Negative	
SOC	19 (50%)	5 (13.2%)	24 (63%)
MOC	10 (26.3%)	4 (10.5%)	14 (37%)
Total	29 (76.3%)	9 (23.7%)	38 (100%)
P. value	0.855		
Pearson's R-value	-0.088		

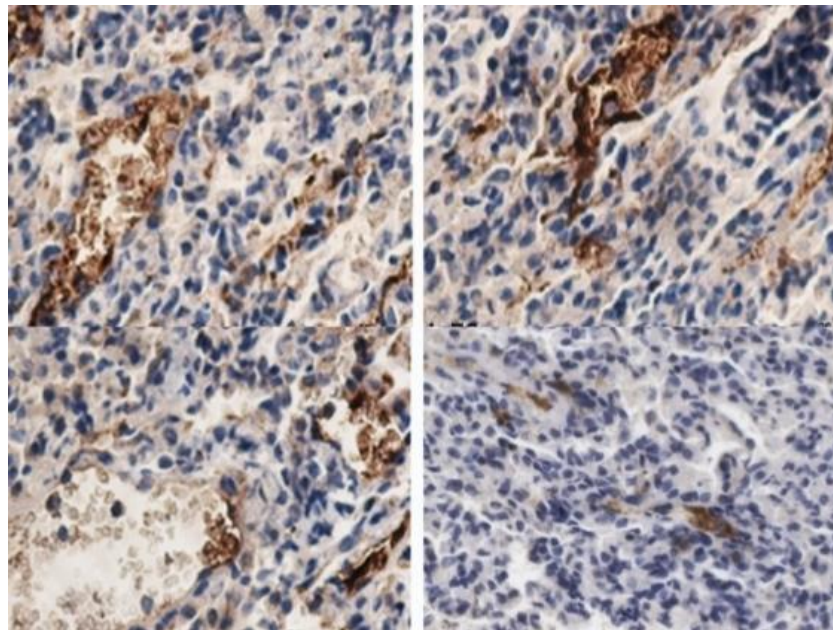


Figure 1 Immunohistochemistry showing nuclear and cytoplasmic positivity for VEGF in the neoplastic cells of ovarian Mucinous, and serous carcinoma (×400)

Table 4 Relation of VEGF Immunohistochemical-result with age group

Age group	VEGF Immuno-histochemical result (n=38)		Total
	Negative n=9	Positive n=29	
26-36	2 (5.3%)	0	2 (5.3%)
37-47	2 (5.3%)	9 (23.7%)	11 (28.9%)
48-58	4 (10.5%)	12 (31.6%)	16 (42.1%)
59-70	1 (2.6%)	8 (21%)	9 (23.7%)
Total	9 (23.7%)	29 (76.3%)	38 (100%)
Chi-Square p-value	0.04		
Pearson's R-value	0.263		

4. DISCUSSION

Vascular endothelial growth factor (VEGF) is a potent endothelial mitogen that acts through the various VEGF receptors (VEGFRs) that are present on the endothelial cells of the blood vessels and lymphatics. Numerous human tumors, such as lung, breast, and colorectal cancers, have been shown to overexpress VEGF and possess VEGFRs during the neoplastic transformation (Sopo et al., 2019; Seidman et al., 2003). Whereas the consequence of VEGF on tumor angiogenesis is well established, the other implications of VEGF in tumorigenesis largely depend on the tumor. A very few studies in literature have reported VEGF overexpression in ovarian cancers (Ranjbar et al., 2015 and, Chambers et al., 2010) and its role in ovarian serous carcinogenesis is not well established.

A very few studies in literature have reported VEGF overexpression in ovarian cancers (Ranjbar et al., 2015 and Chambers et al., 2010) and its role in ovarian serous carcinogenesis is not well established. Hence, we attempted to investigate the pattern of VEGF expression in mucinous and serous carcinomas and to correspond it with the age of the participants. Our finding reveals that most diagnosed participants were between the age group 47- 58years old 16(42.1%) and decrease in younger age this finding supported by (Edmondson et al., 2001) who noted that the incidence rate of ovarian cancer has slow down and decreased in younger. The majority of cases were serous ovarian carcinoma 24(63%), 19(50%) out of them were positive for the marker and while 4(10.5%) out of 14 (37%) were positive with marker in mucinous ovarian carcinoma this finding indicate that the expression of VEGF in serous ovarian carcinoma is higher than mucinous ovarian cancer, but the result was insignificant (P- value=0.855) that come in contact with (Abu-Jawdeh et al., 1996) who revealed that VEGF mRNA and protein were expressed by the neoplastic cells in all the malignant tumors studied showing potent expression of mRNA.

Serous tumors had variable VEGF mRNA expression. No definite expression of VEGF was seen in mucinous borderline tumors. No potent expression of VEGF was seen in normal ovarian cortex, these results found that VEGF plays a crucial role in the angiogenesis and prognosis associated with ovarian tumor. There was difference in VEGF expression between the serous and mucinous ovarian cancer which disagree with (Inan et al., 2004), they suggest that the excessive expression of VEGF and its receptors were not statistically different in both serous and mucinous adenocarcinomas. While they conclude that VEGF may play a critical role in ovarian cancer biology, with possible impact on cell proliferation and angiogenesis. Many studies approved the possible role of survivin and VEGF in development of neither ovarian nor breast cancer (Acimovic et al., 2016 and Afaf et al., 2020).

One possible explanation for this could be the nature of the VEGFRs that are expressed on the tumor cells. As previously stated; VEGF acts on several receptors which are expressed on the tumor cells as well as on endothelial cells during neoplastic transformation. There are three different kinds of VEGFRs namely: VEGFR-1 (Flt), VEGFR-2 (Flt-1/KDR) and VEGFR-3 (Flt-4). The functions of such three receptors differ. VEGFR1 promotes tumor migration, VEGFR2 enhances mitogenic signaling, and VEGFR3 is found primarily on lymphatic endothelial cells (Lalla et al., 2003; Masood et al., 2001 and Wong et al., 2003). Therefore, the type of receptor expressed by the neoplastic cells determines the effect of VEGF in the tumor, so the expression of these receptors is variable in human cancers; this could explain our findings in Sudanese female with ovarian cancer.

5. CONCLUSION

There statistically association between VEGF expression and advance age, while did not correlated with histological types of ovarian cancer. Further study should be done involving large sample size of ovarian cancer using advance technique such as ovarian cancer Vm RNA testing.

Limitations of the study

The present study enrolled only a total of 38 participants, as the Sudanese population more than 30 million people according to the last Census. Many of the variables investigated depended on patients' records. This study did not incorporate control group, other types of ovarian cancers, as well as stage and grade of cancer, Extensive clinical and diagnostics research efforts regarding more advanced laboratory analysis are contraindicated.

Acknowledgment

This publication was supported by the Deanship of scientific research at Prince Sattam bin Abdul-Aziz University. Special thanks extended to Al Neelain University Faculty of Medical Laboratory Sciences, department of Histopathology and cytology. The authors acknowledge with thanks and appreciation the participants who all contributed samples to the study.

Conflict of interest

The author declares that there is no conflict of interest.

Funding

This study has not received any external funding.

Authors' contribution

MO (sample collection, laboratory work, and purchasing reagents)

AA (supervision, proof reading)

SA (Laboratory works, and Calibration of machines)

LB (Scientific writing, publication)

Data and materials availability

All data associated with this study are present in the paper.

REFERENCES AND NOTES

1. Abu-Jawdeh G, Faix J, Niloff J, Tognazzi K, Manseau E, Dvorak H, Brown L. Strong expression of vascular permeability factor (vascular endothelial growth factor) and its receptors in ovarian borderline and malignant neoplasms. *Lab Invest* 1996; 74(6):1105-15.
2. Acimovic M, Vidakovic S, Milic N, Jeremic K, Markovic M, Milosevic-Djeric A, Lazovic-Radonjic G. Survivin and VEGF as Novel Biomarkers in Diagnosis of Endometriosis. *J Med Biochem* 2016; 35(1):63-68.
3. Afaf A, Nazik E, Sara A, Abdulaziz A, Hisham A, Lienda E. Immunohistochemical Expression of Survivin and Ki-67 as tumor markers in Breast Cancer infected females: A cross-sectional prospective study. *Pharmacophore* 2020; 11(5):41-45
4. Bull L, Schorge O, Peyton J, Shigematsu H, Xiang L, Miller S, Lea S. Implications of EGFR inhibition in ovarian cancer cell proliferation. *Gynecol Oncol* 2008; 109(3):411-7.
5. Chambers K, Clouser C, Baker F, Roe J, Cui H, Brewer A, Hatch D, Gordon S, Janicek F, Isaacs D, Gordon N, Nagle B, Wright M, Cohen L, Alberts S. Overexpression of tumor vascular endothelial growth factor A may portend an increased likelihood of progression in a phase II trial of bevacizumab and erlotinib in resistant ovarian cancer. *Clin Cancer Res* 2010; 16(21):5320-8.
6. Choi H, Song Y, Choi J, Park A, Kang H, Kim J, Lee W, Kim G, Lee H, Bae S. Prognostic significance of VEGF expression in patients with bulky cervical carcinoma undergoing neoadjuvant chemotherapy. *BMC Cancer* 2008; 8:295.
7. Edmondson J, Monaghan M. The epidemiology of ovarian cancer. *Int J Gynecol Cancer* 2001; 11(6):423-9.
8. Frumovitz M, Schmeler M, Malpica A, Sood K, Gershenson M. Unmasking the complexities of mucinous ovarian carcinoma. *Gynecol Oncol* 2010; 117:491-6.
9. Henderson T, Webber M, Sawaya F. Screening for Ovarian Cancer: Updated Evidence Report and Systematic Review for the US Preventive Services Task Force. *JAMA* 2018; 319(6):595-606.
10. Inan S, Vatanserver S, Celik-Ozenci C, Sancı M, Dicle N, Demir R. Immuno localizations of VEGF, its receptors flt-1, KDR and TGF-beta's in epithelial ovarian tumors. *Histol Histopathol* 2006; 21(10):1055-64.
11. Jacobs J, Menon U. Progress and challenges in screening for early detection of ovarian cancer. *Mol Cell Proteomics* 2004; 3(4):355-66.

12. Kaya A, Ciledag A, Gulbay E, Poyraz M, Celik G, Sen E, Savas H, Savas I. The prognostic significance of vascular endothelial growth factor levels in sera of non-small cell lung cancer patients. *Respir Med* 2004; 98(7):632-6.
13. Kumaran C, Jayson C, Clamp R. Antiangiogenic drugs in ovarian cancer. *Br J Cancer* 2009; 100(1):1-7.
14. Lalla V, Boisoneau S, Spiro D, Kreutzer L. Expression of vascular endothelial growth factor receptors on tumor cells in head and neck squamous cell carcinoma. *Arch Otolaryngol Head Neck Surg* 2003; 129(8):882-8.
15. Masood R, Cai J, Zheng T, Smith L, Hinton R, Gill S. Vascular endothelial growth factor (VEGF) is an autocrine growth factor for VEGF receptor-positive human tumors. *Blood* 2001; 98:1904-13.
16. Parkin M, Bray F, Ferlay J, Pisani P. Global cancer statistics, 2002. *CA Cancer J Clin* 2005; 55(2):74-108.
17. Ranjbar R, Nejatollahi F, Nedaeh Ahmadi S, Hafezi H, Safaie A. Expression of Vascular Endothelial Growth Factor (VEGF) and Epidermal Growth Factor Receptor (EGFR) in Patients with Serous Ovarian Carcinoma and Their Clinical Significance. *Iran J Cancer Prev* 2015; 8(4):e3428.
18. Ravikumar G, Crasta A. Vascular endothelial growth factor expression in ovarian serous carcinomas and its effect on tumor proliferation. *South Asian J Cancer* 2013; 2:87-90.
19. Robati M, Ghaderi A, Mehraban M, Shafizad A, Nasrolahi H, Mohammadianpanah M. Vascular endothelial growth factor (VEGF) improves the sensitivity of CA125 for differentiation of epithelial ovarian cancers from ovarian cysts. *Arch Gynecol Obstet* 2013; 288(4):859-65.
20. Roett MA, Evans P. Ovarian cancer: an overview. *Am Fam Physician* 2009; 80(6):609-16.
21. Seidman D, Kurman J, Ronnett M. Primary and metastatic mucinous adenocarcinoma in the ovaries: incidence in routine practice with a new approach to improve intraoperative diagnosis. *Am J Surg Pathol* 2003; 27:985-93.
22. Sopo M, Anttila M, Hämäläinen K, Kivelä A, Ylä-Herttuala S, Kosma M, Keski-Nisula L, Sallinen H. Expression profiles of VEGF-A, VEGF-D and VEGFR1 are higher in distant metastases than in matched primary high grade epithelial ovarian cancer. *BMC Cancer* 2019; 19(1):584.
23. Tanaka K, Babic I, Nathanson D, Akhavan D, Guo D, Gini B, Dang J, Zhu S, Yang H, De Jesus J, Amzajerdi N, Zhang Y, Dibble C, Dan H, Rinkenbaugh A, Yong H, Vinters V, Gera F, Cavenee K, Cloughesy F, Manning D, Baldwin S, Mischel S. Oncogenic EGFR signaling activates an mTORC2-NF- κ B pathway that promotes chemotherapy resistance. *Cancer Discov* 2011; 1(6):524-38.
24. Vasudevan G, Jaiprakash P, Guruvare S, Samanta N. Ovarian borderline mucinous tumor with squamous overgrowth: An unusual finding with review of literature. *Indian J Pathol Microbiol* 2018; 61(2):261-263.
25. Wong C, Wellman L, Lounsbury M. VEGF and HIF-1 alpha expression are increased in advanced stages of epithelial ovarian cancer. *Gynecol Oncol* 2003; 91: 513-517.
26. Wright D, Shah M, Mathew L. Fertility preservation in young women with epithelial ovarian cancer. *Cancer* 2009; 115:4118-26.