

Bilateral nasal myxoma in 22 years psychiatric male - a case report

Reda Daoud¹, Khalid Alqarni^{2✉}, Malak satam Alanazi³,
Ahad M Almohammadi², Sultan alharthy⁴

ABSTRACT

Introduction: Myxoma is a benign tumor with slow-growth and rare presence in the maxilla and mandible. *Case presentation:* We report a case report of a 22-years old male who presented with a persistent bilateral progressive nasal obstruction, and he was diagnosed as a bilateral allergic fungal polyp; he showed no improvement on corticosteroid treatment. Functional endoscopic sinus surgery (FESS) used to treat the patient, which is known for using in the treatment of chronic severe conditions of the nasal sinuses, antrochoanal polyps, and sinonasal tumors. FESS was found to be efficient in the treatment of nasal myxoma, with complete removal of the tumor with no recurrence on follow-up. *Conclusion:* complete removal of the tumor with no recurrence on follow-up and longer follow-up should be established to ensure no long-term recurrence.

Keywords: Nasal, Myxoma, FESS, Recurrence.

To Cite:

Reda Daoud, Khalid Alqarni, Malak satam Alanazi, Ahad M Almohammadi, Sultan alharthy. Bilateral nasal myxoma in 22 years psychiatric male a case report. *Medical Science*, 2021, 25(109), 520-524

Author Affiliation:

¹Otolaryngologist consultant, King Salman Armed Force Hospital in north western region, Tabuk, Saudi Arabia

²Medical intern, University of Tabuk, Tabuk, Saudi Arabia

³Otolaryngology service resident, King Fahad Specialty Hospital, Tabuk, Saudi Arabia

⁴Otolaryngologist consultant and Head of department, King Salman Armed Force Hospital in north western region, Tabuk, Saudi Arabia

✉Corresponding author

Medical intern, University of Tabuk, Tabuk, Saudi Arabia,
Email: dkh.q5@hotmail.com

Peer-Review History

Received: 25 January 2021

Reviewed & Revised: 27/January/2021 to 22/February/2021

Accepted: 23 February 2021

Published: March 2021

Peer-review Method

External peer-review was done through double-blind method.

1. INTRODUCTION

Myxomas are slow-growing and benign tumors, locally aggressive and invasive, with a high recurrent rate (Taneja et al., 2012). The most common site of myxomas is the heart, soft tissue, and rarely occurs in the bone (Manne et al., 2012; Kumar et al., 2020). Head and neck soft tissue myxomas are rare, with less than 50 cases reported (Quintal et al., 1994), and the majority of this neoplasia in the neck and head arising from the mandible and maxilla (Allphin, et al., 1993). Sinonasal myxomas are a rare benign connective tissue neoplasm that is derived from primitive mesenchyme (Manne et al., 2012). The distribution of age ranges from 11 months to 8th decade with a peak incidence of 25 to 35 years, and the female slightly predominance is seen (Sreeja et al., 2015). Histologically, these lesions are characterized by spindle wedge or satellite shaped (Hunchaisri, 2002). Here, we present a patient with a rare form of soft tissue myxoma arising in the sinonasal in a psychiatric 22-year-old male patient.

2. CASE PRESENTATION

A 22 years old male with known bronchial asthma, eosinophilic granulomatosis with polyangiitis (EGP), and schizophrenia on medication



(valproic acid 500mg, quetiapine 400 mg, haloperidol 5mg) was admitted to our center. The patient was suffering from nasal obstruction long time, but he was tolerating and doing well until four years before referral to the otolaryngology department for treatment. He came with his brother complain of bilateral progressive nasal obstruction associated with headache, mouth breathing, a decrease of smell and snoring, not associated with fever, epistaxis, or visual complaints, no other otolaryngologic symptoms. Clinical examination was done by anterior Rhinoscopy, which showed a pink fleshy mass protruding from the anterior concha, complete filling the nasal cavity of both side. It was soft to firm in nature but didn't bleed on touch. There was deviated nasal septum (DNS) to the left side. He was diagnosed as a bilateral allergic fungal sinusitis case, and he received local corticosteroids with follow up after three months, and CT was requested (figure 1). After three months, the patient came with the same presentation without improvement on medication.

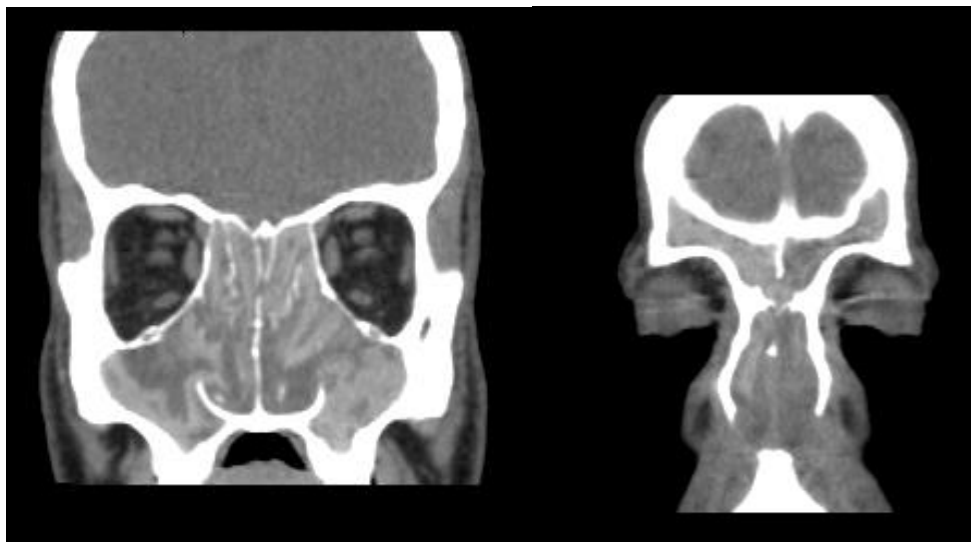


Figure 1 Coronal ct sinus show opacitfication of all PNS with extension into the nasal cavity. Nasal polyp obliterates almost both nasal cavity and extended posterior the choanal opening on both sides.

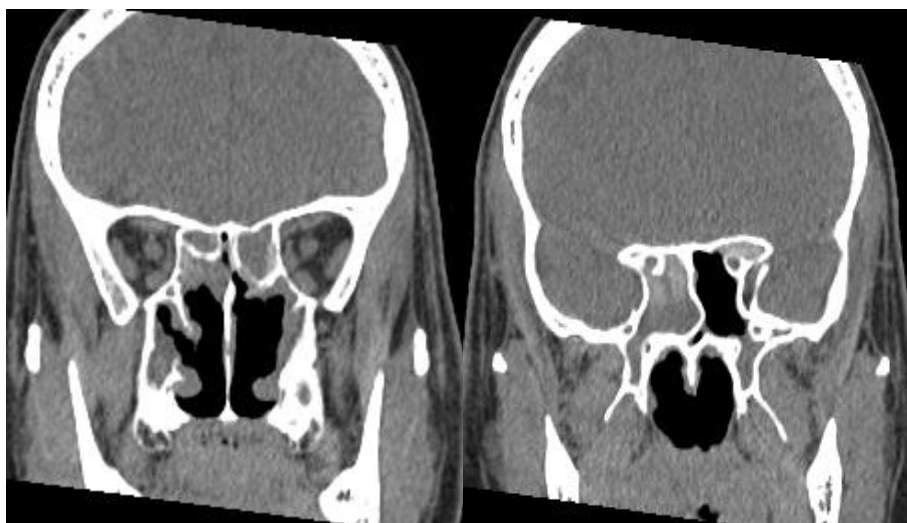


Figure 2 Postoperative follow up ct scan after 1 year of operation show redaction of opacitfication of the maxillary sinus but still seen marked opacity of maxillary sinus by hypertrophy mucosa. Still seen almost total opacitfication of the frontal, ethmoidal and Right sphenoid sinus.

The patient was prescribed for cefuroxime of 1.5 gm, Dexamethasone 8mg/ 8 hours intravenously for the hospital course. The patient was consulted pre-operatively for internal medicine for bronchial asthma and his psychiatric illness. The management plan was to remove the polyp with a surgical clearance, which was done by using the microdebrider associated Endoscopic Sinus Surgery (FESS) approach to clear the nasal cavity and paranasal sinuses completely. A left external ethmoidectomy incision was

done for clipping of the left anterior ethmoidal artery because of intranasal injury during the surgery. He was consulted post-operatively for ophthalmology for intra-operative left eye swelling to assess the vision and optic nerve and eye mobility. The patient was prescribed post-operatively for Fluticasone 125mcg/ Salmeterol 25 Mcg, two Puff, inhalation, Bid, for 120 days, Salbutamol 100 Mcg/Puff inhaler, two Puff inhalations, Q8H, for seven days, Cefuroxime 500 Mg tablet, one tablet orally, Q12h for seven days, Paracetamol 500 Mg tablet, two tablets orally, Q6H for seven days, Triamcinolone/Nyst/Neomycin/Gramicidin 15 Gm, one topical application, Q12H for seven days, Itraconazole 100Mg capsule, two capsules orally, Q12H for 30 days, and Mometasone Furoate Monohydrate nasal spray 0.05%, two nasal doses, Q12 H for 30 days. The patient was discharged with normal vision, suffering no bleeding or fever, and stable conditions. The biopsy was taken for histopathological analysis; the sections obtained showed multiple polypoid lesions composed of uniform spindle cells forming sheets and clusters within markedly myxoid stroma with occasional blood vessels. Few cellular foci with collagenous stroma but no large bizarre nuclei were found. There was no mitosis but microscopic foci of tumor necrosis. Follow up was done with endoscopy performance at three months in the clinic. The flexible nasopharyngeal scope showed no true polyps; the patient didn't show any recurrence. Clinically the patient is asymptomatic and disease-free, as shown by computed tomography (CT) (figure 2) and rhinoscopy (figure 3 and 4) one-year after surgery.

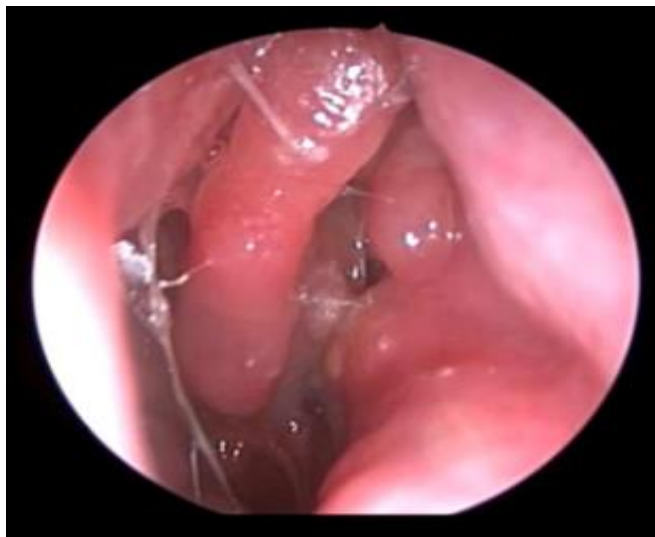

Figure 3 Rhinoscopy of one side of the nose after 1year post FESS

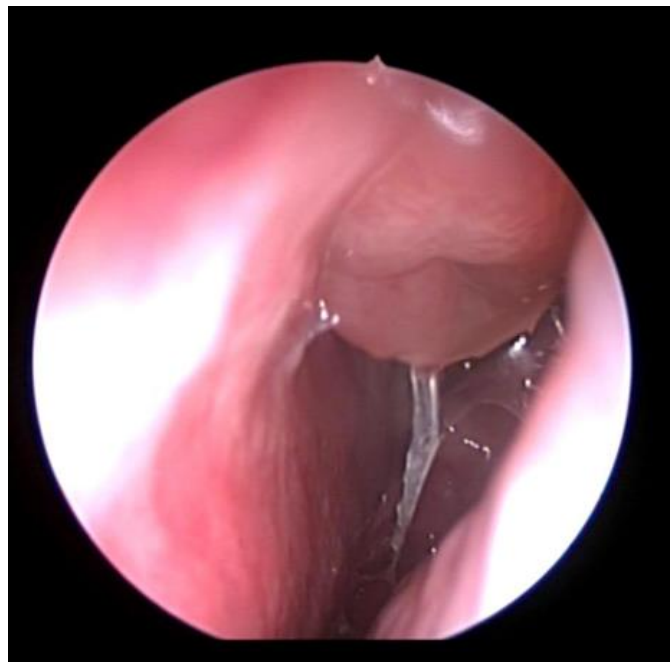

Figure 4 Rhinoscopy of the other side of the nose after 1year post FESS

3. DISCUSSION

Neck and head myxoma are rare cases encountered; neck and head myxoma involve maxillary sinus (Wenig, 2016). There are 75% of myxoma arise in the maxilla or mandible (Dhawan & Agarwal, 2014). The diagnosis of tumors and illustrating their characteristic features of specific histological types can be performed using an imaging approach (Ali et al., 2015). Our patient was examined using a CT scan. Myxoma on examination appears nodular, gray-weight, glistening masses of variable consistency, without true capsule, and ranging from gelatinous to firm in nature (Mewar et al., 2020). Sinonasal myxoma on histological examination consists of a non-encapsulated, similar, loose proliferation of stellated, round, or spindled cells with thin cytoplasmic projection and hyperchromic small nuclei (Quintal et al., 1994). In our patients, he was found having a fleshy mass filling the nasal cavity of both sides and protruding from the anterior concha. On histological examination, the right nasal polyp was large, whereas the left polyp was multiple polypoid masses; both polyps were soft to firm with the mucoid grey white rubbery surface. The definitive treatment of myxoma is the complete removal of the tumor (Dhawan & Agarwal, 2014). It was demonstrated that incomplete tumor removal contributes to the recurrence, and the conservative surgical excision was suggested as the treatment option (Kadlub et al., 2014). As myxoma tends to recur, extensive surgical removal should be used with the removal of a small amount of surrounding tissue. The resection of the tumor requires a meticulous surgical technique with excellent exposure to ensure the complete removal of the tumor (Dhawan & Agarwal, 2014).

FESS is a surgical technique that is the most commonly used for the treatment of serious unresponsive conditions of the nasal sinuses. This approach results in symptoms improvements among up to 90% of patients, as it removes the obstruction tissues (Behiry et al., 2019). The current case was treated by FESS for complete surgical clearance of the nasal cavity and paranasal sinus. The patient was prescribed anti-fungal medications. The patient was doing well, with no re-growth of the tumor at three months of follow-up. This indicates the success of the FESS for the complete removal of bilateral nasal myxoma with no recurrence. In a previous case report of a 50-years old female with bilateral progressive nasal obstruction, it was found that the tumor was visualized using an endoscopic approach, and this assisted in the complete clearance (Dhawan & Agarwal, 2014). It was reported in 31 cases with a benign tumor of paranasal and nasal cavities that using an endoscopic approach as the choice of treatment were reported with total resection with no recurrence (Ali et al., 2015). One study reported that FESS resulted in the improvement of the quality of life of patients with chronic rhinosinusitis (Behiry et al., 2019).

4. CONCLUSION

FESS is efficient and the best choice of the treatment of nasal myxoma, where it results in complete removal of the tumor with no recurrence on follow-up. However, longer follow-up should be established to ensure no long-term recurrence.

Authors' contributions

Reda Daoud: Primary author read and approved the final manuscript.

Khalid alqarni, Malak satam Alanazi, Ahad M. Almohammadi Sultan alharthy: This work carried out in collaboration among all authors. All authors read and approved the final manuscript.

Conflict of interests

The authors declare no conflict of interest.

Ethical approval and patient consent

Ethical approval was taken by ethics research committee at Armed Forces Hospital Northwestern region, Tabuk, Saudi Arabia. (Ethic ID number KSAFH-REC-2020-342). Written and oral informed consent was obtained from all individual participants included in the study.

Funding

This paper received no external funding.

Abbreviations

Functional endoscopic sinus surgery	FESS
Deviated nasal septum	DNS
Eosinophilic granulomatosis with polyangiitis	EGP

Data and materials availability

All data associated with this study are present in the paper.

REFERENCES AND NOTES

1. Ali M, Nabil M, Safa N, Hela D, Sameh M, Cyrine Z, Ghassen C, Rania BM, Khemaies A, Sonia B. Diagnosis and management of benign tumors of nasal and paranasal cavities: 31 cases. *Egypt J Otolaryngol* 2015 1; 31(1):4.
2. Allphin AL, Maniglia AJ, Gregor RT, Sawyer R. Myxomas of the mandible and maxilla. *Ear Nose Throat J* 1993; 72(4):280-4.
3. Behiry EA, Elshazly HM, Abdel-Shafy IA, Adel Hussein H. Evaluation of quality of life after Functional Endoscopic Sinus Surgery (FESS) in chronic rhinosinusitis patients in Menoufia Governorate. *Egypt. J Ear Nose Throat Allied sci* 2019; 20(3): 131-6.
4. Dhawan S, Agarwal N. Myxoma of nose and paranasal sinuses. *Curr Med Res Pract* 2014 1; 4(6):286-8.
5. Hunchaisri, N. Myxoma of the nasal cavity and paranasal sinuses: report of a case. *J Med Assoc Thai* 2002; 85(1), 120-124.
6. Kadlub N, Mbou VB, Leboulanger N, Lepointe HD, Ansari E, L'hermine AC, Davrou J, Vazquez MP, Picard A. Infant Odontogenic Myxoma: a specific entity. *J Craniomaxillofac Surg* 2014; 42(8):2082-6.
7. Kumar A, Kushwaha S, Jaiswal S, Singh P, Deshpande R, Acharya S. Unusual presentation of Cardiac Myxoma. *Med Sci*, 2020, 24(102), 521-525
8. Manne, R., Kumar, V., Venkata Sarath, P., Anumula, L., Mundlapudi, S., & Tanikonda, R. Odontogenic Myxoma of the Mandible. *Case Rep Dent* 2012, 1-4.
9. Mewar P, González-Torres KE, Jacks TM, Foss RD. Sinonasal Myxoma: A Distinct Lesion of Infants. *Head Neck Pathol.* 2020; 14(1):212-9.
10. Quintal MC, Tabet JC, Oligny L, Russo P. Oral soft tissue myxoma: report of a case and review of the literature. *J Otolaryngol.* 1994; 23(1):42-5.
11. Taneja T, Saxena S, Reddy V, Goel A, Taneja N. Odontogenic myxoma: A rare case involving maxillary sinus with a brief review of the literature. *Indian J Oral Sci.* 2012; 3(2):107-.
12. Vijayabanu B, Sreeja C, Bharath N, Aesha I, Kannan VS, Devi M. Odontogenic myxoma of maxilla: A rare presentation in an elderly female. *J. Pharm. Bioallied Sci* 2015; 7(Suppl 2):S759.
13. Wenig B. Sinonasal myxoma and fibromyxoma. *Atlas of head and neck pathology.* 3rd ed. Philadelphia: Elsevier; 2016; 118–22.